

AN UNUSUAL CASE OF CEREBRAL VENOUS SINUS THROMBOSIS IN A  
YOUNG WOMAN WITH TETRALOGY OF FALLOTDr. Asmatullah<sup>1</sup>, Dr. Maryam Khalil<sup>2</sup>, Dr. Mohammad Khalid Hamidi<sup>3</sup>, Dr. Nasiruddin<sup>4</sup>,  
Dr. Mansoor Iqbal<sup>5</sup>, Prof. Mazhar Badshah<sup>6</sup><sup>1,2,5,6</sup>Pakistan Institute of Medical Science  
<sup>3,4</sup>King Edward Medical University/Mayo HospitalDOI: <http://doi.org/10.5281/zenodo.20536359>**Keywords**

Unusual, Cerebral Venous Sinus, Thrombosis, Young Woman With Tetralogy Of Fallot.

**Article History**

Received on 16 March 2026

Accepted on 24 April 2026

Published on 30 May 2026

Copyright @Author

Corresponding Author: \*

Dr. Maryam Khalil

<sup>2</sup>[Maryamkhalil401@gmail.com](mailto:Maryamkhalil401@gmail.com)**Abstract****Background:**

Tetralogy of Fallot (TOF) is the most common cyanotic congenital heart disease. In low- and middle-income countries, delayed diagnosis and limited access to surgical correction can lead to long-term complications. Among these, cerebral venous sinus thrombosis (CVST) is a rare but potentially life-threatening neurological event, particularly in uncorrected TOF patients.

**Case Presentation:** We report the case of a 21-year-old female with a known history of uncorrected TOF, diabetes mellitus, and hypertension, who presented with headache, vomiting, new-onset seizures, altered level of consciousness, and right-sided weakness. Imaging studies revealed a left parietal intraparenchymal hemorrhage with features consistent with late subacute CVST. Further evaluation confirmed classical TOF findings on echocardiography. She was managed with intravenous fluids, antiepileptics, antibiotics, and supportive care.

**Discussion:** CVST in the context of uncorrected TOF remains underrecognized. Chronic hypoxemia, polycythemia, and a hypercoagulable state contribute to the pathogenesis. A review of recent literature reveals a limited number of similar cases, underscoring the rarity of this presentation. This case highlights the need for early neuroimaging and high clinical suspicion when TOF patients present with neurological symptoms.

**Conclusion:**

This case illustrates a rare but serious neurological complication of uncorrected TOF. Clinicians should consider CVST in the differential diagnosis of cyanotic congenital heart disease patients with acute neurological signs. Early detection and prompt management are essential to improving outcomes in such complex cases.

**Introduction:**

Tetralogy of Fallot (TOF) is a cyanotic congenital heart disease characterized by four anatomical anomalies: ventricular septal defect, pulmonary stenosis, right ventricular hypertrophy, and an overriding aorta. Although surgical correction has significantly improved outcomes, patients with uncorrected or late-repaired TOF especially in low- and middle-income countries remain vulnerable to severe complications, both cardiac and neurological [1]. Among the known neurological manifestations, cerebrovascular events, including ischemic stroke, cerebral abscess, and more rarely, cerebral venous sinus thrombosis (CVST), are being increasingly recognized in this population [2,3].

Chronic hypoxemia, polycythemia, and the presence of right-to-left shunts in TOF create a hypercoagulable state that predisposes patients to paradoxical embolism and venous thrombosis [4]. CVST is an uncommon but life-threatening cerebrovascular condition, often presenting with headache, seizures, focal neurological deficits, and altered consciousness. In patients with congenital heart disease, especially those with co-existing systemic conditions like infective endocarditis, the diagnostic complexity and risk of delayed management increase considerably [4]. Pediatric and young adult patients with uncorrected TOF are particularly susceptible to both infective and thromboembolic complications due to prolonged cyanosis and impaired immune response [2,3].

Despite its rarity, cases of CVST in TOF are increasingly being reported, particularly from resource-limited settings where delayed access to corrective cardiac surgery is common [1]. This underscores the need for heightened clinical vigilance when such patients present with acute neurological symptoms. A recent update on CVST in Asian populations has emphasized region-specific risk factors, diagnostic challenges, and treatment barriers, reinforcing the importance of early

neuroimaging and multidisciplinary management in these cases [5].

In this case report, we describe a 21-year-old female with uncorrected TOF who presented with seizures, altered sensorium, and right-sided weakness. Neuroimaging revealed cerebral venous sinus thrombosis complicated by late subacute intraparenchymal hemorrhage. The case highlights the intersection of rare neurological complications with congenital cardiac disease and serves as a reminder of the broader systemic impact of uncorrected TOF in adult survivors.

**Case study:**

A 21-year-old female from Rawalpindi, with a known history of Tetralogy of Fallot (TOF) since childhood, as well as comorbid diabetes mellitus (DM) and hypertension (HTN), presented to the emergency department with complaints of headache, vomiting, and two episodes of new-onset seizures within a day. She also had altered level of consciousness and right-sided body weakness for one day. She had been married for seven years with a history of two miscarriages. On examination, her Glasgow Coma Scale (GCS) score was 14/15. She had facial puffiness, periorbital edema, and bilateral reactive pupils. Extraocular movements were intact, and her neck was supple. Motor assessment showed decreased activity on the right more than the left side, and bilateral plantar reflexes were downgoing. Chest auscultation revealed bilateral crackles. Her vital signs at presentation included a blood pressure of 150/90 mmHg, pulse rate of 70 bpm, oxygen saturation of 88% on room air, and a random blood sugar of 102 mg/dL.

Initial CT of the brain revealed a mixed-density lesion in the left high parietal region with a dense clot sign and a left transverse sinus hyperdensity, accompanied by perilesional edema. MRI brain with contrast showed a high-signal intensity area in the left parietal region on T1, T2, and FLAIR sequences, along with diffuse edema and no post-contrast enhancement; restricted diffusion on ADC

and DWI sequences was consistent with a late subacute intraparenchymal hemorrhage (Figure 1). EEG demonstrated a diffuse low voltage rhythm with background slowing (Supplemental Figure 1). Magnetic resonance venography (MRV) revealed non visualization of the anterior two thirds of the superior sagittal sinus, consistent with extensive thrombosis. The left sigmoid sinus and left internal jugular vein were also not visualized, indicating associated thrombosis. The left transverse sinus appeared congenitally atretic. A heterogeneous altered MR signal was noted in the left frontal lobe with patchy areas of restricted diffusion and internal gyriiform hypointensity on DWI/ADC sequences, compatible with a left frontal lobe hemorrhagic infarct. Mild contralateral midline shift and adjacent mass effect were present. The inferior sagittal sinus, straight sinus, and right-sided venous sinuses were patent, and no evidence of dural arteriovenous malformation or dural arteriovenous fistula was identified (Figure 2).

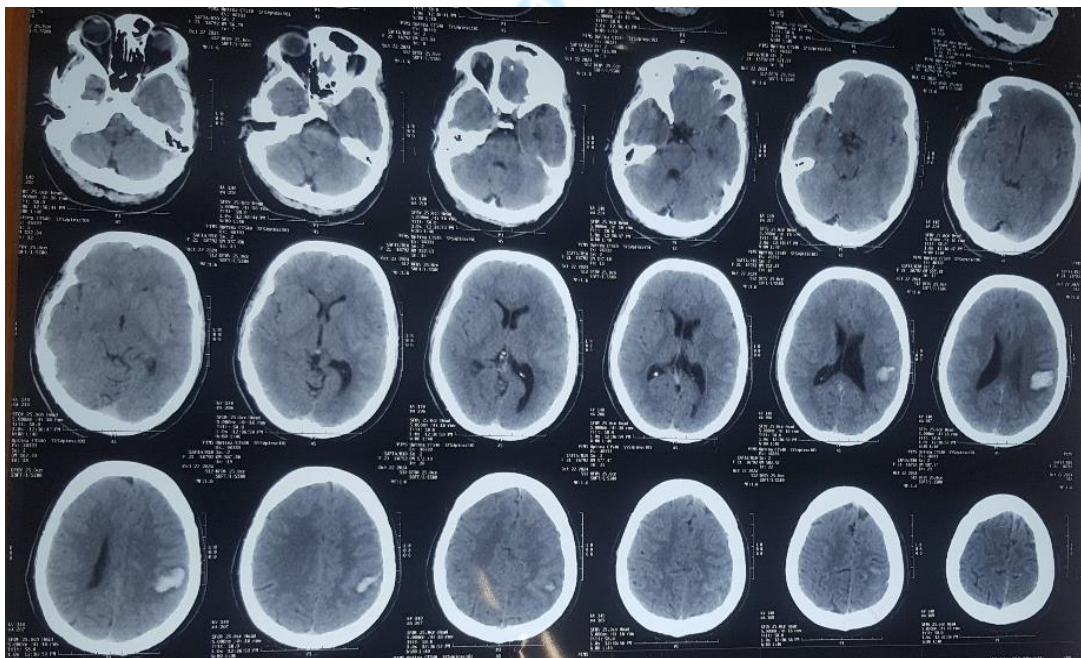
A transthoracic echocardiogram revealed an ejection fraction of 65% with overriding of the

aorta, right ventricular hypertrophy (RVH), ventricular septal defect (VSD), and a bidirectional shunt confirming classical features of TOF.

Laboratory findings showed hemoglobin of 17.5 g/dL, hematocrit 54%, MCV 89.4 fL, WBC 7600/mm<sup>3</sup>, and platelets 212,000/mm<sup>3</sup>.

Serum biochemistry revealed ALT 107 U/L, CPK 142 U/L, urea 20.5 mg/dL, creatinine 0.714 mg/dL, sodium 131.5 mmol/L, and potassium 5.24 mmol/L.

The patient was diagnosed with cerebral venous sinus thrombosis (CVST) in the context of underlying TOF and associated intraparenchymal hemorrhage. During her hospital stay, she was managed with intravenous normal saline (0.9% NaCl 1000 mL twice daily), multiple antiepileptic agents including levetiracetam (500 mg IV TDS), lacosamide (100 mg IV BD), and sodium valproate (500 mg IV TDS), as well as antibiotics including ceftriaxone (1 g IV BD) and metronidazole (500 mg IV TDS). Supportive care included proton pump inhibitor therapy with esomeprazole (40 mg IV OD) and ondansetron (8 mg IV as needed).



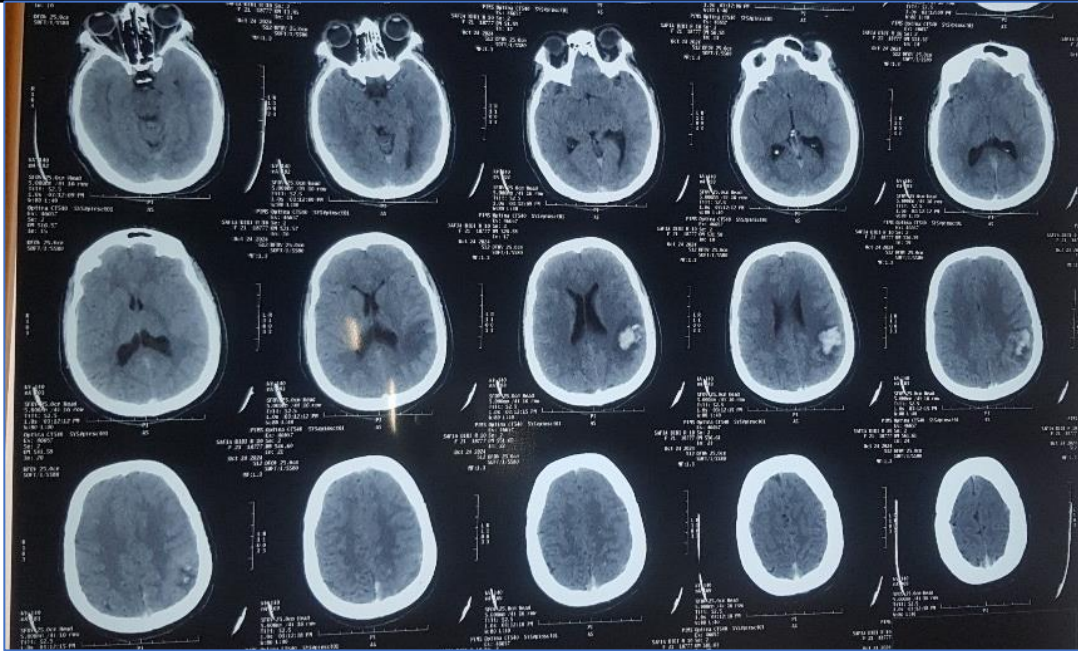


Figure 1, MRI Brain with Contrast: Altered MR signal intensity area in left parietal region. High signal intensity on T1, T2 and FLAIR showing diffuse surrounding edema with no post contrast

enhancement. It is high on ADC and DWI showing diffusion restriction, suggestive of late subacute intraparenchymal haemorrhage.

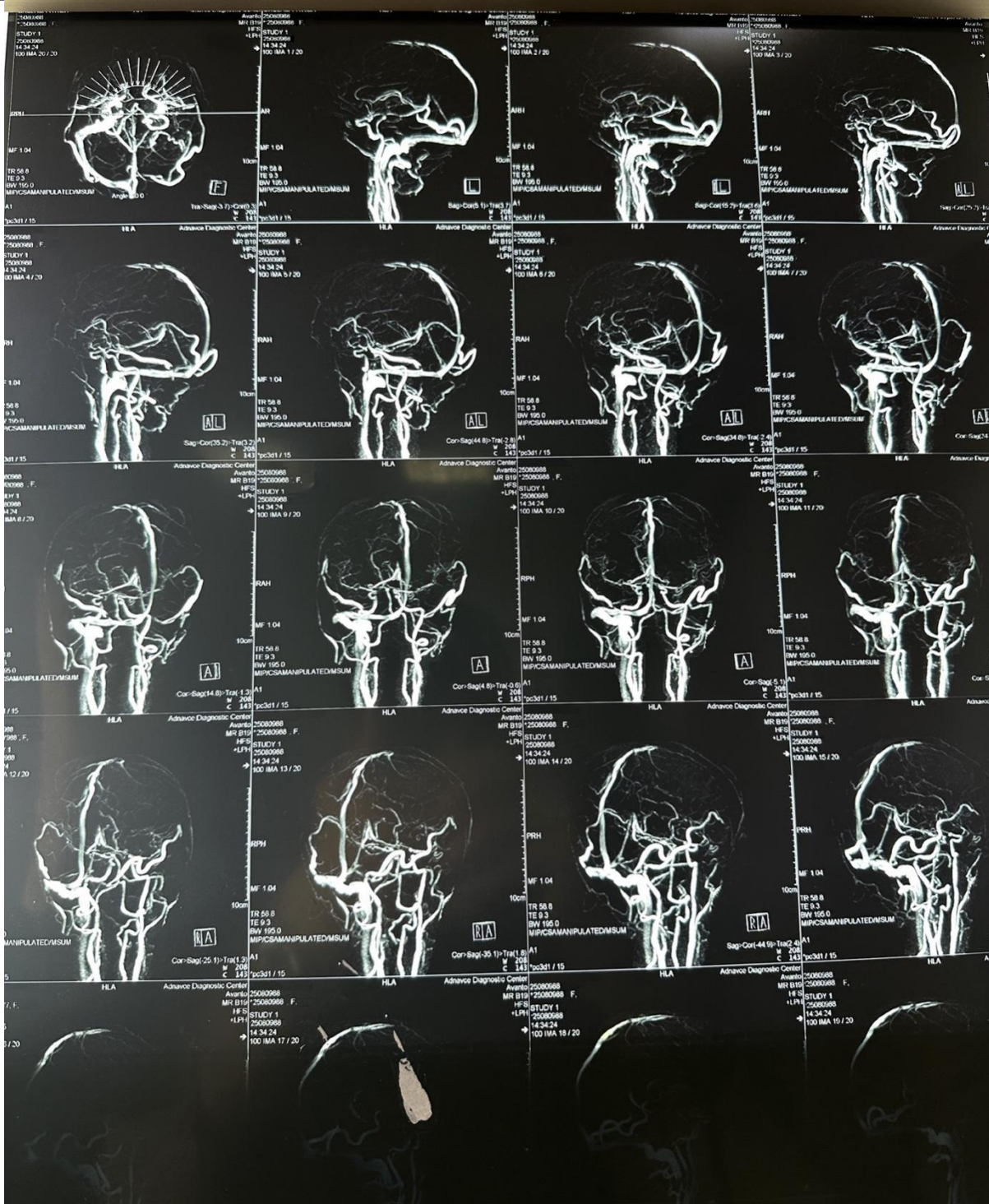

Figure 2, MRV Brain: Non-visualization of the anterior two thirds of the superior sagittal sinus with thrombosis of the left sigmoid sinus and internal jugular vein. Left transverse sinus appears atretic.

Findings are consistent with extensive cerebral venous sinus thrombosis

**Discussion:**

Tetralogy of Fallot (TOF) remains a significant cause of morbidity in low- and middle-income countries, where early diagnosis and surgical correction are often delayed due to limited healthcare infrastructure and access [1]. This delay can result in persistent cyanosis, secondary erythrocytosis, and chronic hypoxia, creating a predisposition to systemic and neurological complications, particularly in patients reaching adulthood without corrective surgery [2].

One such rare but important neurological complication is cerebral venous sinus thrombosis (CVST), which has been reported in the context of uncorrected TOF due to the combination of hyperviscosity, endothelial dysfunction, and a prothrombotic state induced by chronic hypoxemia [4]. In our case, the patient presented with seizures, altered sensorium, and focal neurological deficits clinical features consistent with those described in similar reports of TOF-associated CVST [4].

Although the more commonly described neurologic complications in TOF include brain abscesses and ischemic strokes, as highlighted by Kamabu et al [3]. and Bhatnagar et al., emerging evidence suggests that CVST may be underdiagnosed in this population [2]. Kamabu et al. reported a case of multiple cerebral abscesses in a child with uncorrected TOF, emphasizing the brain's vulnerability in the setting of chronic cyanotic heart disease [3]. Similarly, Bhatnagar et al. documented stroke-like neurological sequelae in pediatric patients with TOF, reinforcing the high neurological risk profile of these patients, even in the absence of traditional vascular risk factors [2].

The possible contribution of infective endocarditis, a recognized complication in cyanotic congenital heart disease, must also be considered. Mishra et al. described a patient with TOF who developed both infective endocarditis and CVST, suggesting that the combination of cardiac and infectious insults can further increase the risk of cerebral thrombosis [4]. Although our patient had no overt

signs of infection, the potential for subclinical endocarditis in similar cases should not be overlooked.

Furthermore, the regional disparity in outcomes is significant. Dib et al. emphasized that patients from resource-limited settings are more likely to present late with complex and multi-system complications due to lack of timely surgical intervention [1]. In parallel, Ta et al. pointed out that CVST remains a frequently under-recognized diagnosis in the Asian context, often due to limited access to neuroimaging and underappreciation of its diverse clinical presentations [5].

In summary, this case adds to the limited but growing body of literature highlighting CVST as a rare but serious complication in patients with uncorrected TOF. It reinforces the need for early neuroimaging in cyanotic heart disease patients presenting with neurological symptoms, and underscores the importance of early surgical correction and long-term follow-up to prevent such life-threatening outcomes [1-4].

#### **Conclusion:**

This case underscores the critical need to recognize cerebral venous sinus thrombosis (CVST) as a rare but serious neurological complication in patients with uncorrected Tetralogy of Fallot (TOF). In resource-limited settings where delayed surgical correction is common, prolonged cyanosis and chronic hypoxemia can predispose patients to a hypercoagulable state, significantly increasing the risk of thrombotic and hemorrhagic cerebral events. Our patient's presentation with seizures, altered consciousness, and focal neurological deficits highlights the importance of maintaining a high index of suspicion for CVST in TOF patients presenting with acute neurological symptoms. Early neuroimaging, timely diagnosis, and multidisciplinary management are essential to preventing long-term morbidity. This case also reinforces the broader public health imperative of improving access to early cardiac surgery and follow-

up care for congenital heart disease in low-resource regions.

**Declaration:**

**Consent for publication**

The patient gave written informed consent for the publication of their clinical details and any accompanying images.

**Availability of data and materials**

All data generated or analyzed during this study are included in this published article. 4.

**Competing interests**

The authors declare that they have no competing interests.

**Funding**

No funding was received for this study.

**References:**

1. Dib N, Chauvette V, Diop MS, Bouhout I, Hadid M, Vò C, et al. Tetralogy of Fallot in Low- and Middle-Income Countries. *CJC Pediatric and Congenital Heart Disease*. 2024 Apr;3(2):67-73.

Bhatnagar S, Kuber R, Naware S, Thind S.

Pediatric stroke: Neurological sequelae in uncorrected tetralogy of fallot. *Ann Med Health Sci Res*. 2013;3(5):27.

Kamabu LK, Sikakulya FK, Kataka LM, Vivalya BNM, Lekuya HM, Obiga DOD, et al. Tetralogy of Fallot complicated by multiple cerebral abscesses in a child: a case report. *J Med Case Rep*. 2024 Dec 1;18(1).

Mishra A, Singh S, Rama Krishna Reddy MM, Anwaar MA, Yadav AS, Ayirebi-Acquah E, et al. Common Consequences of Uncommon Congenital Heart Disease: Exploring the Trilogy of Fallot With Infective Endocarditis and Cerebral Venous Thrombosis. *Cureus*. 2023 Sep 14;

5. Miraclin T A, Bal D, Sebastian I, Shanmugasundaram S, Aaron S, Pandian JD. Cerebral Venous Sinus Thrombosis: Current Updates in the Asian Context. Vol. 14, *Cerebrovascular diseases extra*. 2024. p. 177-84.