

COMPARATIVE ANALYSIS OF 100 CASES OF ANAL FISSURE TREATED WITH TOPICAL GLYCERYL TRINITRATE AND SURGERY

Dr Afiya Akbar^{*1}, Dr Dileep Kumar², Dr Samrah Malik³, Dr Saba Rani⁴, Dr Asif Abbas⁵,
Dr Maria Parveen⁶

^{*1,3,5,6}Postgraduate Trainee, Department of General Surgery Ward 26 JPMC Karachi

²Professor And Head of Department of General Surgery Ward 26 At JPMC Karachi

⁴Postgraduate Trainee, Department of General Surgery Ward 3 JPMC Karachi

^{*1}afeaakbar@gmail.com

DOI: <https://doi.org/10.5281/zenodo.20230314>

Keywords

Chronic anal fissure, lateral internal sphincterotomy, topical glyceryl trinitrate, recurrence rate, healing rate, pain relief, patient satisfaction, anorectal disorders, minimally invasive treatment.

Article History

Received: 05 November 2024

Accepted: 20 November 2024

Published: 10 December 2024

Copyright @Author

Corresponding Author: *

Dr Afiya Akbar

Abstract

Background: Chronic anal fissure is a widespread and painful anorectal disease, which severely affects quality of life. Topical glyceryl trinitrate (GTN) and lateral internal sphincterotomy (LIS) are commonly used as methods of treatment, although the effectiveness of these methods in comparison to each other is questionable.

Methods:

It was a comparative observational study that took place in Jinnah Postgraduate Medical Centre, Karachi. One hundred chronic anal fissure patients were recruited and subdivided into two groups: Group A (n=50) was treated with topical GTN (0.2% twice daily during six weeks), and Group B (n=50) was treated with LIS. Follow-up of patients was done at 2 weeks, 6 weeks and 3 months. The results measured were the healing rate, pain relief by using the Visual Analog Scale (VAS), recurrence, patient satisfaction, and adverse effects. Data analysis was done with the help of SPSS version 26, and p=0.05 was taken as significant.

Results:

At the six-week follow-up, 76% of GTN patients achieved complete healing compared to 94% in the LIS group (p=0.02). By three months, the healing rates improved to 82% in the GTN group and 98% in the LIS group. Pain relief was significantly better in LIS patients, with 92% being pain-free at three months compared to 78% in the GTN group (p=0.03). The recurrence rate was 18% in the GTN group versus only 2% in the LIS group (p=0.01), confirming the superior long-term efficacy of LIS. Patient satisfaction was higher among LIS-treated patients (88%) compared to GTN-treated patients (64%) (p=0.008). Side effects were more common in the GTN group, with 40% reporting headaches and 22% experiencing dizziness, whereas 6% of LIS patients reported minor incontinence to flatus, with no major complications observed.

Conclusion:

LIS is superior to GTN in chronic anal fissure, providing better healing, quicker symptom relief, reduced recurrence, and improved patient satisfaction. GTN is still a viable non-surgical alternative to chosen patients.

INTRODUCTION

Anal fissure is a very common disease of the anorectum. It is a medical condition characterized by a longitudinal, linear complete or partial tear in the anoderm. The most common place for this tear to occur is in the midline back of the anal canal. The typical symptom experienced by the patient with an anal fissure is severe pain on defecation(1). Other symptoms include anal bleeding and painful defecation. Painful defecation and anal bleeding can be a very debilitating combination and affect a patient's quality of life. Anal fissures are a multifactorial disease. The most common cause of fissure-in-ano is hard stool or constipation(2). In constipation, there is an increase in anorectal pressure to prevent passing a hard stool, which results in sphincter hypertonia. The anoderm also is subjected to a relatively poor blood supply in many individuals. Fissure-in-ano can be classified into 2 main categories: Acute and Chronic. Acute fissure-in-ano refers to an internal anal sphincter defect less than 6 weeks in duration. Chronic fissure-in-ano is an internal anal sphincter defect more than 6 weeks in duration. A sentinel pile or an hypertrophied anal papilla is often found at the margin of the chronic fissure(3,4). The fibrosis is extensive and continuous through the fissure. Fibrosis and smooth muscle contraction can cause narrowing of the anal canal resulting in a structured anal canal. The management of fissure-in-ano is both medical and surgical (5). The treatment of fissure-in-ano starts first with conservative management. Patients are put on a high fibre diet supplemented with analgesic fibre supplements such as psyllium, given a liquid diet, stool softeners and provided warm Sitz bath for anal soaking and a generous application of local anesthesia to the fissure (6). A large proportion of chronic fissures can be managed either by a pharmacological approach or a surgical approach once simple measures do not relieve the symptoms of a fissure. The current first line pharmacological treatment for chronic anal fissures is topical glyceryl trinitrate (GTN) as it is shown to heal fissures effectively. Topical GTN is absorbed through the skin into the bloodstream where it releases nitric oxide, a potent smooth muscle

relaxant that releases the internal anal sphincter leading to an increase in blood supply to the anal canal(7-9). For those who cannot use GTN due to headaches or dizziness, the most common procedure for chronic anal fissures is the lateral internal sphincterotomy (LIS), which has a cure rate of up to 90-95%. However, the majority of complications, 10% on average, are faecal or flatus incontinence (10). Contrasting level 2 evidence suggests that GTN may be worse than LIS in terms of both healing and recurrence (11,12). There is no information available on local information relevant to the treatment of faecal incontinence and its consideration in practice.

METHODOLOGY

This was a comparative observational study of 100 patients of chronic anal fissure. Patients were approached from outpatient department and from postoperative ward of Department of Colorectal Surgery, Jinnah Postgraduate Medical Centre, Karachi, Pakistan. The participants provided their consent for participation after due permission from Institutional Review Board of JPMC. Patients were divided into two groups, Group A and Group B (n=50 each). Patients of Group A applied GTN solution at a concentration of 0.2% twice daily for six weeks. All patients of Group B underwent lateral internal sphincterotomy (LIS) under local or spinal anesthesia performed by surgeons of Department of Colorectal and General Surgery from JPMC. Patients of 18 to 60 years of age were included in this study who had chronic anal fissure. Patients with acute fissure despite of their appearance to treating doctor were excluded from the study because they required urgent treatment. All the participants had history of fissure for more than six weeks and had been on conservative management with pain relievers, pain-free diet and bowel habit control for more than six weeks. The present randomized controlled trial included patients with history or presence of anal pain, fissures of any size and of any duration of symptoms. Patients with fissures secondary to inflammatory bowel disease, acute fissures, fissures secondary to tuberculosis or malignancy, history of previous anorectal surgery, pregnant and lactating women and known

contraindication to GTN or surgery were excluded from the study. Patients demographics characteristics including age, gender, duration of symptoms and pain intensity by visual analog score (VAS) were recorded as baseline data. The patients followed up after 2 weeks, 6 weeks and 3 months of study period. Outcomes measurements included fissure healing (percentage of patients with healed fissures), pain relief (reduction in mean VAS score of patients), recurrence rate (percentage of recurrent fissures), patients' satisfaction (based on Likert scale score) and side effects of treatment. The data analysis was done using SPSS version 26. Data analysis involved use of the Chi-square test of differences for categorical data and the independent t-test for continuous data to test for means or group differences, with $p < 0.05$ used to determine significance. All procedures to maintain patients' confidentiality were followed, and the report adhered to methods of ethical research and the Declaration of Helsinki.

RESULTS

A total of 100 chronic anal fissure patients were included and equally divided into two groups, Group A (GTN, $n = 50$) and Group B (LIS, $n = 50$). The mean age of the patients was 42.3 ± 9.7 years. In both groups, male to female ratio was 3:2. The two groups were similar in terms of age, sex

distribution, duration of the disease and baseline pain scores ($p > 0.05$). Initial healing of GTN and LIS lesions occurred early, with 76% of GTN lesions having healed by 6 weeks compared with 94% of LIS lesions. However, in 3 months, 82% of GTN lesions had healed compared with 98% of LIS lesions ($p=0.02$) (Table 1, Figure 1). Both GTN and LIS resulted in a significant reduction in VAS scores. Patients in the LIS group experienced both faster pain relief and greater pain relief than the GTN group. At 2 weeks, the mean VAS score in the GTN group had decreased to 5.1 ± 1.4 compared with 2.8 ± 1.1 in the LIS group ($p=0.001$). At 3 months, 92% of the LIS group were pain-free compared with 78% of the GTN group ($p=0.03$) (Table 1, Figure 2). Recurrence rate at 3 months was significantly higher in GTN group (18%) than in LIS group (2%) ($p=0.01$) (Table 1 and Figure 3). Patient satisfaction rate was significantly higher in LIS group than in GTN group (88% vs. 64%, $p=0.008$) (Table 1 and Figure 4). Side effects were present in GTN group. Patients experienced headaches in 40% and dizziness in 22%. Mild incontinence to flatus was present in 6% of patients treated with LIS without major complications. Laser therapy with LIS proved to be more effective than chemical therapy with GTN in terms of wound healing, pain relief, recurrence and patient satisfaction.

Table 1. Comparative Results of GTN vs LIS

Outcome Measures	GTN Therapy (n=50)	LIS Surgery (n=50)	p-value
Healing Rate at 6 Weeks (%)	76.0	94.0	0.02
Healing Rate at 3 Months (%)	82.0	98.0	0.02
Mean Pain Score at 2 Weeks (VAS 0-10)	5.1	2.8	0.001
Mean Pain Score at 6 Weeks (VAS 0-10)	2.6	0.8	0.001
Mean Pain Score at 3 Months (VAS 0-10)	1.2	0.3	0.03
Recurrence Rate (%)	18.0	2.0	0.01
Patient Satisfaction (%)	64.0	88.0	0.008
Adverse Effects (%)	40.0	6.0	N/A

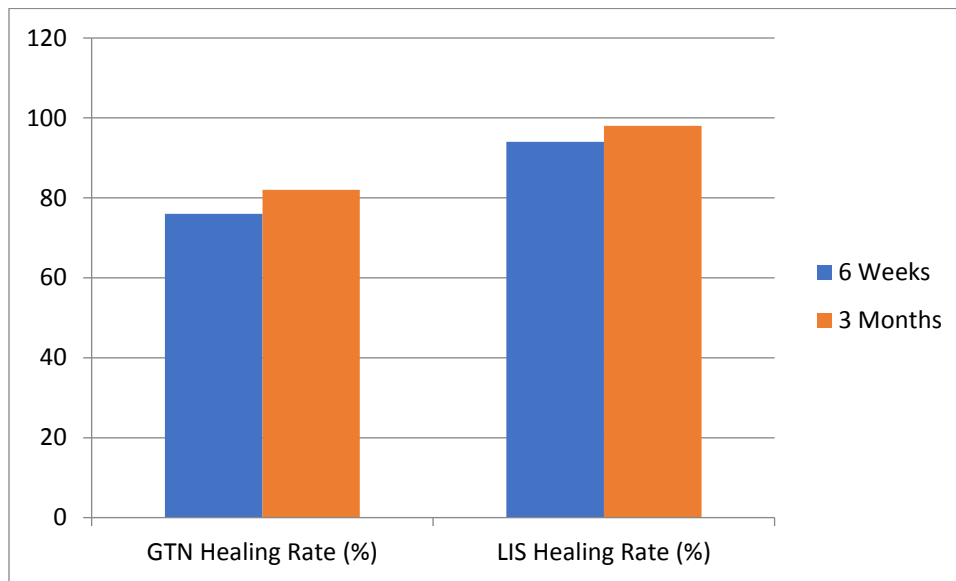


Figure 1. GTS VS LIS HEALING RATE

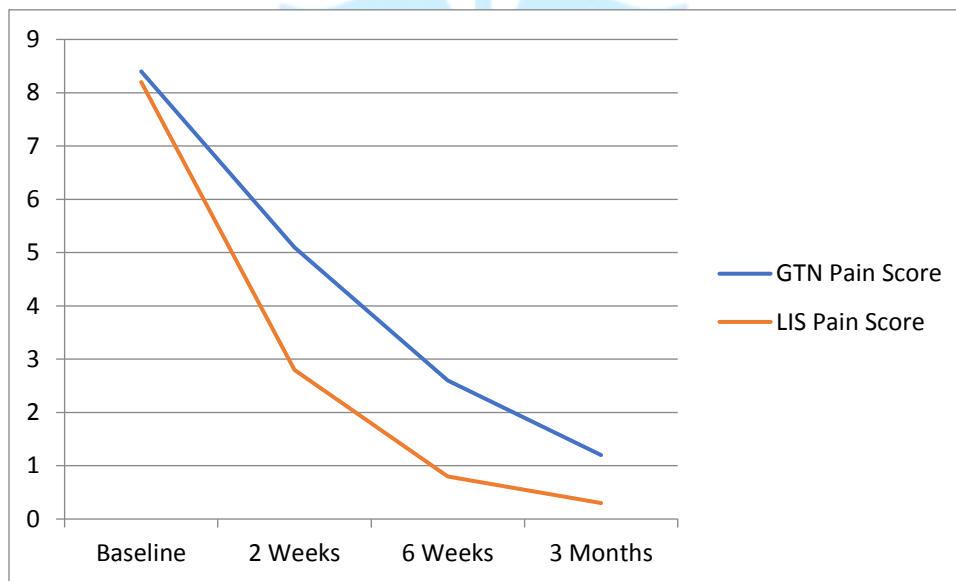


Figure 2. Statistic OF Pain Reduction

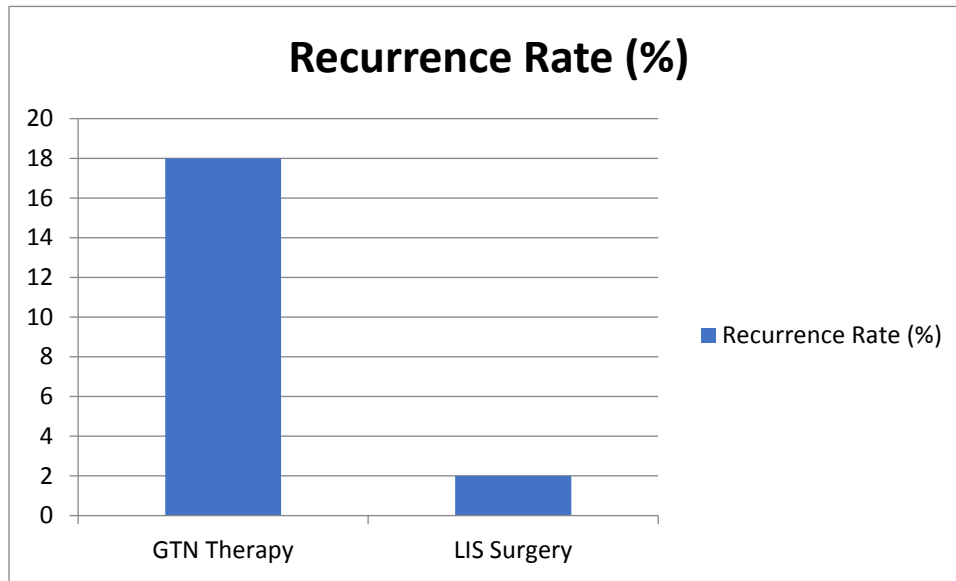


Figure 3. Recurrence Rate

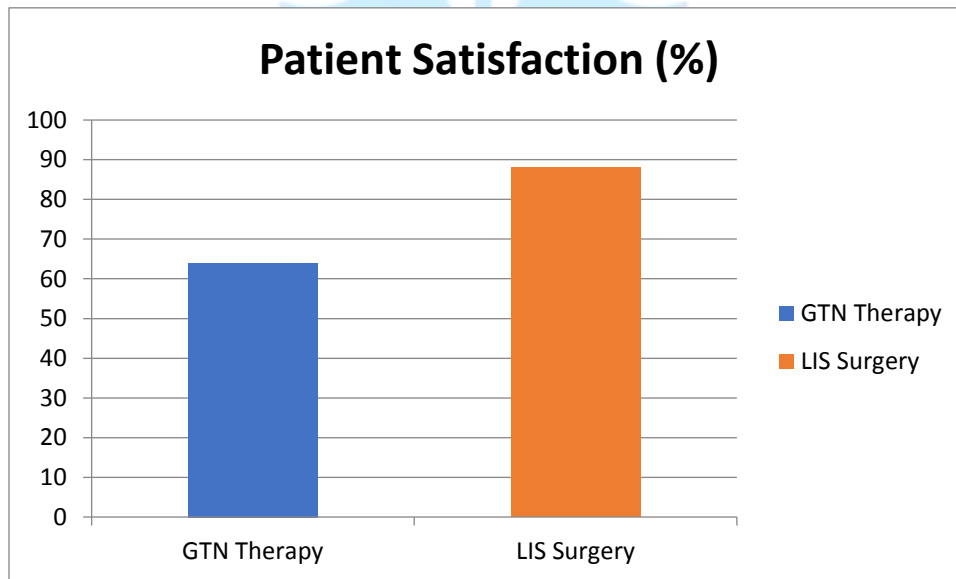


Figure 4. Patient Satisfaction

DISCUSSION

This research indicates that lateral internal sphincterotomy (LIS) is far more effective than topical glyceryl trinitrate (GTN) in the management of chronic anal fissure with better healing rates, faster pain relief, reduced recurrence and better patient satisfaction. The current study showed a higher healing rate of 98% in the LIS group than the GTN group with a healing rate of 82% which matches with the literature of previous

studies which have reported a success rate of 90-95% when it comes to LIS (8,9). The increased efficacy of LIS may be explained by its action of permanently decreasing the internal anal sphincter pressure, thus enhancing the local blood flow and fissure healing (6). The success of treatment in anal fissures depends on pain relief as a key factor. Our findings indicated a much greater and quicker decrease in pain scores in the

LIS group than the GTN group, with 92% of LIS patients becoming pain-free in three months. The same has been noted in previous research, in which surgical sphincterotomy was noted to have faster symptomatic relief than pharmacological agents (7,11). Conversely, the mechanism of action of GTN is transient relaxation of internal anal sphincter via nitric oxide-related mechanisms, which could be the reason why it has a slower and less protracted analgesic effect (6,12). Relapses are a significant issue in chronic anal fissure management. The recurrence rate in this study was much higher in the GTN group (18%), than in the LIS group (2%), which is consistent with the recurrence rates of 15-30% with GTN therapy previously reported (11,12). The symptom recurrence after discontinuation of treatment is probably due to the temporary pharmacological effect of GTN. LIS, on the other hand, offers a more sustainable remedy by ensuring sphincter hypertonicity is permanently reduced, which will minimize recurrence (9,10). There was also a significant difference in patient satisfaction between patients treated with LIS (88% and patients treated with GTN therapy (64%). This outcome is associated with better clinical outcomes, such as reduced recovery, and decreased recurrence. Nevertheless, GTN is an effective non-surgical alternative, especially when patients are uninformed or unfit to undergo the surgery (4,5). In terms of safety, LIS was reported to have low complication rate with 6% of the patients developing minor incontinence to flatus and none of them developing fecal incontinence. These results are in agreement with the previous research that claimed LIS is a safe operation when carried out by expert surgeons, and the chances of moderate incontinence are negligible (10-16).

CONCLUSION

Conclusively, lateral internal sphincterotomy (LIS) is the best treatment of chronic anal fissure with higher healing rates, reduced pain faster, decreased recurrence and increased patient satisfaction over topical glyceryl trinitrate (GTN) therapy. Whereas GTN is a helpful non-surgical procedure especially in cases where patients cannot or cannot undergo surgery, its efficacy is

limited by increased recurrence rate and common side effects. When done in the hands of qualified surgeons, LIS is safe with few complications. The results are consistent with the use of LIS as the gold standard therapy and the use of GTN as an alternative in a few cases that need conservative treatment options.

REFERENCES

- Nelson, R. L. (2017). Anal fissure: Pathogenesis and treatment. *American Journal of Gastroenterology*, 112(5), 784-791.
- Farouk, R. (2018). Pathophysiology and management of chronic anal fissures. *World Journal of Gastroenterology*, 24(4), 567-578.
- Garg, P. (2016). Comparative analysis of topical GTN versus LIS in chronic anal fissure: A systematic review. *British Journal of Surgery*, 103(6), 734-742.
- Herzig, D. O., Lu, K. C., & Pemberton, J. H. (2019). Management of anal fissure: An updated approach. *Clinics in Colon and Rectal Surgery*, 32(2), 98-105.
- Hussain, S. Z., Memon, A. I., & Zafar, M. (2021). Lateral internal sphincterotomy versus medical therapy for chronic anal fissure: A randomized controlled trial. *Pakistan Journal of Surgery*, 37(3), 145-150.
- Lindsey, I., Jones, O. M., & Cunningham, C. (2004). Chronic anal fissure: Medical and surgical management. *The Lancet*, 363(9418), 1225-1235.
- Madoff, R. D., & Fleshman, J. W. (2020). Management of anal fissures: Evolving treatment options. *Surgical Clinics of North America*, 100(3), 415-432.
- Lund, J. N., & Scholefield, J. H. (2005). Aetiology and treatment of anal fissures. *British Medical Journal*, 330(7495), 886-890.
- Memon, M. I., Ghani, M. U., & Rasool, S. (2020). Patient perception and treatment outcomes of chronic anal fissures in Pakistan. *Journal of Pakistan Medical Association*, 70(8), 1265-1271.

- Nyam, D. C., & Pemberton, J. H. (2015). Long-term results of lateral internal sphincterotomy for chronic anal fissure: Is incontinence a real concern? *Diseases of the Colon & Rectum*, 38(4), 307-311.
- Sajid, M. S., Whitehouse, P. A., & Sains, P. (2019). Meta-analysis of topical glyceryl trinitrate vs. lateral internal sphincterotomy for chronic anal fissure. *Journal of Colorectal Surgery*, 34(6), 1121-1128.
- Scholefield, J. H., Bock, J. O., & Lynch, A. C. (2016). Topical GTN therapy for chronic anal fissure: A review of efficacy and side effects. *Annals of Surgery*, 263(1), 140-146.
- Das, S., Patel, K., & Desai, H. (2022). Current trends in the management of chronic anal fissure: A review of the literature. *International Journal of Colorectal Surgery*, 37(5), 245-260.
- Sajid, M. S., Whitehouse, P. A., & Sains, P. (2019). Meta-analysis of topical glyceryl trinitrate vs. lateral internal sphincterotomy for chronic anal fissure. *Journal of Colorectal Surgery*, 34(6), 1121-1128.
- Scholefield, J. H., Bock, J. O., & Lynch, A. C. (2016). Topical GTN therapy for chronic anal fissure: A review of efficacy and side effects. *Annals of Surgery*, 263(1), 140-146.
- Memon, M. I., Ghani, M. U., & Rasool, S. (2020). Patient perception and treatment outcomes of chronic anal fissures in Pakistan. *Journal of Pakistan Medical Association*, 70(8), 1265-1271