Volume 4, Issue 3, 2026

Frontier in Medical & Health Research

ISSN: (e) 3007-1607 (p) 3007-1593

EFFECT OF CURCUMA ON CORNEAL CURVATURE CHANGES IN PSORIATIC PATIENTS

Fatima Faiz[*1], Nimra Gull[2]

[*1]*MPhil Optometry, Department of Optometery Faculty of Medicine & Allied Health Sciences, The University of Faisalabad, Pakistan*

[2]*Associate Professor (Supervisor), Department of Optometery Faculty of Medicine & Allied Health Sciences, The University of Faisalabad, Pakistan*

[2]https://orcid.org/0000-0002-0091-158X

DOI: https://doi.org/10.5281/zenodo.18950505

Keywords

Psoriasis, Curcuma longa, Curcumin, Dry eye disease, Tear breakup time, Schirmer test, Keratometry, Ocular surface inflammation.

Article History

Received: 11 January 2026
Accepted: 24 February 2026
Published: 11 March 2026

Copyright @Author

Corresponding Author: *
Fatima Faiz

Abstract

Background:

Psoriasis is a chronic immune-mediated inflammatory disorder frequently associated with ocular surface disturbances, including tear film instability, reduced tear secretion, and subtle corneal alterations. Despite increasing recognition of these complications, safe adjunctive therapies targeting inflammation-related ocular dysfunction remain limited. Curcumin, the principal bioactive compound of Curcuma longa, *possesses well-documented anti-inflammatory and antioxidant properties that may offer therapeutic benefit in inflammation-driven ocular surface disease.*

Objective:

To evaluate the effect of oral Curcuma longa *tincture supplementation on corneal curvature, tear film stability, and tear production in patients with psoriasis.*

Methods:

This prospective interventional study was conducted at Madina Teaching Hospital and included 30 patients with clinically diagnosed psoriasis aged 25–40 years. Baseline ophthalmic assessment included keratometry, Tear Break-Up Time (TBUT), and Schirmer I test. Participants received 12 drops of Curcuma longa *tincture twice daily for three months. Follow-up evaluations were performed at monthly intervals. Changes across time points were analyzed using repeated measures ANOVA with Greenhouse–Geisser correction. Statistical significance was set at $p < 0.05$.*

Results:

All evaluated parameters demonstrated progressive and statistically significant improvement over the study period. Mean TBUT increased from 5.62 ± 0.31 seconds at baseline to 10.61 ± 0.34 seconds at three months ($p < 0.001$), indicating marked enhancement in tear film stability. Schirmer test values improved from 7.65 ± 0.35 mm to 10.35 ± 0.43 mm ($p < 0.001$), approaching normal tear secretion levels. Keratometric readings showed a gradual reduction from 43.64 ± 0.78 D to 43.11 ± 0.78 D ($p < 0.001$), suggesting stabilization

Frontier in Medical & Health Research

ISSN: (e) 3007-1607 (p) 3007-1593

and mild flattening of corneal curvature. No significant adverse effects were reported during the intervention.

Conclusion:

Oral Curcuma longa *tincture supplementation was associated with significant improvements in tear quality, tear quantity, and corneal parameters in psoriatic patients over three months. These findings support the potential role of curcumin as a safe adjunctive therapy for managing inflammation-related ocular surface dysfunction in psoriasis. Larger randomized controlled trials are warranted to confirm these preliminary findings and to establish standardized treatment protocols.*

INTRODUCTION

Psoriasis is a long-term, immune-mediated inflammatory disorder that primarily affects the skin but is now widely recognized as a systemic disease with multi-organ involvement. Clinically, it is characterized by erythematous plaques covered with silvery scales, resulting from abnormal keratinocyte proliferation and persistent inflammatory activity. In addition to causing visible skin lesions, psoriasis significantly affects physical comfort, emotional wellbeing, and quality of life. The condition is also linked with several comorbidities, including psoriatic arthritis, metabolic syndrome, cardiovascular disease, and ocular complications.

Several clinical subtypes of psoriasis have been described, including plaque psoriasis, guttate psoriasis, inverse psoriasis, pustular psoriasis, and erythrodermic psoriasis. Among these, plaque psoriasis (psoriasis vulgaris) is the most common form, representing the majority of cases worldwide. It typically involves extensor surfaces such as the elbows, knees, scalp, and lower back. Other forms may appear under specific triggers; for example, guttate psoriasis is often associated with streptococcal infections and is more common in younger individuals. Inverse psoriasis commonly affects intertriginous areas such as the axillae and groin, while pustular and erythrodermic variants may present with severe systemic manifestations requiring urgent management.

Globally, psoriasis affects approximately 2–3% of the population. However, prevalence rates differ across regions and ethnic groups, with higher rates reported in populations of European ancestry and lower prevalence observed in many Asian and African regions. In Pakistan, large national epidemiological data are limited, but hospital-based studies indicate that psoriasis is not uncommon and frequently affects young adults. The chronic course of the disease, along with the psychosocial burden and associated systemic complications, makes it an important public health concern.

The onset of psoriasis can occur at any age, but it is often described as having two peak periods. Early-onset psoriasis commonly appears in late adolescence or early adulthood and is often associated with a stronger genetic predisposition and more severe disease. Late-onset psoriasis generally occurs after the age of 50 and may follow a milder course. Although psoriasis can affect both males and females, some studies suggest slightly higher rates in males. Beyond the physical symptoms, psoriasis can have profound psychological effects, including low self-esteem, social withdrawal, anxiety, and depression, particularly due to its visible nature and chronic relapsing pattern.

The underlying pathophysiology of psoriasis is strongly linked to immune dysregulation, particularly involving the IL-23/Th17 inflammatory axis. The inflammatory cascade begins when antigen-presenting cells, such as dendritic cells, become activated and stimulate naïve T-cells. This promotes the differentiation of Th17 cells, which release pro-inflammatory cytokines including interleukin-17 (IL-17), tumor necrosis factor-alpha (TNF-α), and interleukin-22 (IL-22). These mediators accelerate keratinocyte proliferation, disrupt normal epidermal differentiation, and promote the development of psoriatic plaques. Chronic systemic inflammation

Frontier in Medical & Health Research
ISSN: (e) 3007-1607 (p) 3007-1593

is also reflected in raised inflammatory markers such as erythrocyte sedimentation rate (ESR) and C-reactive protein (CRP), supporting the concept that psoriasis extends beyond the skin and can influence multiple organs.

Among the systemic manifestations, ocular involvement is clinically significant but often underrecognized. Patients with psoriasis may develop a variety of eye-related complications, including blepharitis, conjunctivitis, uveitis, and dry eye disease (DED). Uveitis is particularly relevant in individuals with psoriatic arthritis and may lead to serious visual impairment if not identified and treated promptly. Similarly, chronic ocular surface inflammation can result in persistent discomfort, irritation, photophobia, and reduced visual function. These ocular symptoms can further compromise quality of life, especially when combined with systemic disease burden.

Dry eye disease is frequently observed in psoriasis, and its development is believed to be associated with inflammation of tear-producing glands and ocular surface tissues. Dysfunction of lacrimal glands may reduce aqueous tear secretion, while inflammatory changes can also disturb the stability of the tear film. As a result, patients may experience burning sensation, foreign body sensation, redness, and fluctuating vision. Additionally, ocular surface dryness may increase the risk of epithelial injury, corneal abrasion, and secondary infections. Chronic irritation often leads patients to rub their eyes, which may further worsen corneal surface integrity and contribute to corneal structural alterations.

The cornea plays a central role in visual performance due to its transparency and refractive power. Corneal curvature determines how light is focused onto the retina, and even minor changes in its shape can cause refractive errors such as astigmatism, myopia, or irregular vision. Corneal curvature may be altered by genetic factors, environmental influences, mechanical stress, or systemic inflammatory diseases. In psoriasis, persistent inflammatory activity and elevated cytokine levels may influence corneal tissue remodeling. Cytokines such as TNF-α and IL-17 can affect stromal collagen organization, epithelial healing, and extracellular matrix regulation. This may lead to corneal thinning, irregularity, scarring, or altered keratometric readings, potentially affecting visual acuity and ocular comfort.

To evaluate ocular surface and corneal changes, several diagnostic methods are commonly used in clinical practice. Tear production is often assessed using the Schirmer test, in which a standardized filter paper strip is placed in the lower conjunctival fornix and the wetting length is measured after five minutes. Values below the normal range suggest reduced tear secretion and aqueous-deficient dry eye. Tear film stability is evaluated using Tear Break-Up Time (TBUT), which measures the interval between a blink and the appearance of the first dry spot after fluorescein instillation. TBUT values below 10 seconds generally indicate tear film instability and evaporative dry eye. For corneal curvature assessment, keratometry remains a widely used method, measuring the anterior corneal radius based on reflected images. However, keratometry typically evaluates only the central cornea and may not capture peripheral irregularities. Advanced imaging tools such as corneal topography and Scheimpflug imaging provide a more comprehensive three-dimensional analysis, including elevation maps, astigmatism profiles, and corneal thickness distribution.

Given the inflammatory nature of psoriasis and its impact on ocular tissues, there is increasing interest in supportive therapies that can reduce inflammation and oxidative stress. Curcuma longa, commonly known as turmeric, is a traditional medicinal plant widely used in South Asia. Its main active component, curcumin, has demonstrated anti-inflammatory, antioxidant, antimicrobial, and immunomodulatory effects in various experimental and clinical studies. Curcumin has been shown to inhibit key inflammatory pathways, including nuclear factor-kappa B (NF-κB), which regulates the expression of pro-inflammatory cytokines such as TNF-α, IL-6, and IL-17. By suppressing these mediators, Curcuma longa may reduce inflammatory activity and slow down keratinocyte hyperproliferation, which is central to psoriatic lesion development.

In addition to its dermatological benefits, Curcuma longa has also gained attention for its

Frontier in Medical & Health Research
ISSN: (e) 3007-1607 (p) 3007-1593

potential role in ocular health. Ocular tissues are highly sensitive to oxidative stress and inflammatory damage, and chronic inflammation may contribute to conditions such as dry eye disease, corneal degeneration, and impaired epithelial repair. Curcuma has been reported to support tissue healing by reducing oxidative injury, modulating inflammatory mediators, and influencing enzymes such as matrix metalloproteinases (MMPs), which are involved in corneal extracellular matrix breakdown. These mechanisms suggest that Curcuma longa may help improve tear film function and preserve corneal structure in inflammatory systemic diseases.

Curcuma is available in several forms, including powders, capsules, topical preparations, and tinctures. Tincture preparations are often preferred in complementary medicine because they provide flexible dosing and potentially faster absorption compared to solid formulations. However, curcumin's natural bioavailability is limited due to rapid metabolism and poor intestinal absorption. Therefore, extraction methods, alcohol-based formulations, and combination approaches are often used to enhance therapeutic effects.

Considering the increasing recognition of ocular involvement in psoriasis and the need for supportive therapies with fewer adverse effects, it is important to explore natural anti-inflammatory agents that may benefit ocular surface health. This study was therefore designed to evaluate the effect of Curcuma longa tincture on tear film parameters and corneal curvature in patients with psoriasis. Tear film stability and secretion were assessed using TBUT and the Schirmer test, while corneal curvature changes were evaluated using keratometry readings over a three-month treatment period.

REVIEW OF LITERATURE

Psoriasis is increasingly recognized as a systemic inflammatory disorder with significant ocular involvement. Several clinical studies have demonstrated that patients with psoriasis exhibit alterations in tear film stability, ocular surface integrity, and corneal structure, even in the absence of obvious visual complaints.

Corneal structural changes in psoriasis have been explored using advanced imaging modalities. Akçam et al. (2019) evaluated corneal topographic parameters in patients with psoriasis vulgaris using Pentacam imaging. Although mean keratometric values did not significantly differ from healthy controls, indices reflecting corneal asymmetry were elevated in psoriatic eyes. Notably, a considerable proportion of patients demonstrated topographic patterns suggestive of keratoconus or keratoconus suspects. These findings suggest that chronic systemic inflammation may subtly influence corneal architecture before overt ectatic disease becomes clinically apparent.

Beyond topography, corneal biomechanics have also been investigated. Edris et al. (2020) reported reduced corneal hysteresis and corneal resistance factor in psoriatic patients compared to controls, indicating compromised biomechanical strength. The authors proposed that persistent exposure to inflammatory mediators such as TNF-α and IL-17 may contribute to stromal remodeling and altered corneal integrity. These observations support the concept that psoriasis affects deeper ocular tissues, not only the surface.

Tear film dysfunction is among the most consistently reported ocular findings in psoriasis. Multiple cross-sectional and observational studies have demonstrated significantly reduced Tear Break-Up Time (TBUT) and elevated tear osmolarity in psoriatic patients compared with healthy individuals (Demirci et al., 2017; Yu et al., 2011). While Schirmer test results have shown variable outcomes across studies, tear instability appears to be a prominent feature. Prospective analyses further indicate a correlation between psoriasis severity (PASI score) and ocular surface impairment, reinforcing the systemic inflammatory basis of tear film disruption (Kharolia et al., 2022; Singh et al., 2022). Importantly, several studies reported that ocular abnormalities may persist even when dermatologic symptoms improve, highlighting the need for adjunctive therapies targeting ocular inflammation.

Given the inflammatory mechanisms underlying both psoriasis and ocular surface disease, curcumin has gained attention as a potential

Frontier in Medical & Health Research
ISSN: (e) 3007-1607 (p) 3007-1593

therapeutic agent. Clinical trials evaluating bioavailable oral curcumin formulations have demonstrated significant anti-inflammatory effects in dermatologic conditions. Antiga et al. (2015) reported that adjunctive curcumin therapy improved PASI scores in plaque psoriasis and reduced pro-inflammatory cytokine levels. Similarly, curcumin supplementation has shown beneficial effects in ocular inflammatory disorders, including uveitic macular edema and chronic anterior uveitis, with improvements in visual acuity and reduction in inflammatory markers (Allegri et al., 2022; Rossi et al., 2019).

Experimental studies provide mechanistic support for these clinical findings. In vitro investigations on human corneal epithelial cells have demonstrated that curcumin suppresses NF-κB activation, reduces pro-inflammatory cytokine expression, and protects against oxidative stress–induced cellular damage (Luo et al., 2009; Wang et al., 2021). Animal models have further shown accelerated corneal epithelial healing and reduced inflammatory infiltration following curcumin administration (Gupta et al., 2019; Guo et al., 2016). Additionally, randomized controlled trials in dry eye disease have reported improvements in TBUT, tear film parameters, and symptom scores with oral bio-enhanced curcumin supplementation (Vanathi et al., 2020).

Collectively, existing literature establishes three important considerations: psoriasis is associated with measurable tear film instability and corneal alterations; chronic inflammation likely contributes to these ocular changes; and curcumin possesses anti-inflammatory and cytoprotective properties capable of influencing ocular tissues. However, limited studies have specifically examined the effect of Curcuma longa on corneal curvature and tear film parameters in psoriatic patients. This gap forms the basis of the present investigation.

MATERIALS AND METHODS

Study Design

This study was designed as a quasi-experimental interventional trial to evaluate the effect of Curcuma longa tincture on tear film parameters and corneal curvature in patients diagnosed with psoriasis.

Study Setting

The research was carried out at Madina Teaching Hospital, Faisalabad, Pakistan. All ocular examinations and follow-up assessments were conducted in the ophthalmology/optometry clinical setup under controlled environmental conditions.

Study Duration

The study was conducted over a period of nine months, from September 2024 to May 2025. The active intervention period for each participant was three months, with monthly follow-up visits.

Sample Size

A total of 60 eyes from 30 patients were included in the study. The sample size was calculated using RaoSoft sample size estimation with a 95% confidence level and a 5% margin of error. Both eyes of each eligible participant were assessed and included for analysis.

Sampling Technique

Participants were recruited using purposive sampling. Patients visiting the dermatology department and diagnosed with psoriasis were referred for ocular screening, and those meeting eligibility criteria were enrolled.

Eligibility Criteria

Inclusion Criteria

Participants were included if they fulfilled the following criteria:

- Clinically diagnosed cases of mild to moderate psoriasis.
- Age between 20 and 35 years.
- Both male and female participants were eligible.
- Individuals willing to follow the dosage regimen and attend all follow-up visits.

Exclusion Criteria

Patients were excluded if they had any of the following:

- Presence of systemic disease other than psoriasis.

Frontier in Medical & Health Research
ISSN: (e) 3007-1607 (p) 3007-1593

- Any ocular pathology other than dry eye or corneal curvature alteration.
- Current use of ocular lubricants or topical eye medication.
- History of allergy or hypersensitivity to turmeric/Curcuma longa.
- Pregnant or lactating females.
- Contact lens wearers.
- Uncooperative patients or those unable to complete follow-ups.
- Use of systemic medications that could influence inflammatory status or ocular parameters, such as methotrexate, cyclosporine, oral retinoids, or other immunosuppressants.

Study Materials and Instruments

The following clinical instruments were used during the study:

- LogMAR visual acuity chart (Sunsex International)
- Manual keratometer (ZEISS)
- Slit lamp biomicroscope (Haag-Streit)
- Schirmer strips (Pricon)
- Fluorescein strips (Pricon)
- Stopwatch
- Curcuma longa tincture (oral formulation)

Intervention: Curcuma longa Tincture

Curcuma longa was administered in tincture form throughout the study. Each participant received 12 drops orally, twice daily, after meals. The tincture was diluted in half a cup of water before intake to improve tolerability and absorption.

The dosage was selected according to homoeopathic pharmacopeial recommendations and supported by published safety ranges. The supplementation was continued for three consecutive months. All participants were instructed to avoid additional supplements or anti-inflammatory medications during the trial period. Compliance was monitored through weekly telephonic reminders and confirmation during monthly clinical visits. No participant reported significant adverse effects during the intervention period.

Clinical Examination and Outcome Measures

All participants underwent ocular examination at baseline and during three follow-up visits (at 1 month, 2 months, and 3 months). The primary outcome measures included tear film stability, tear secretion, and corneal curvature.

To minimize examiner bias and variation, all tests were performed by the same investigator using standardized techniques and consistent slit lamp settings.

Slit Lamp Examination

A slit lamp biomicroscope was used for detailed assessment of the anterior segment, including eyelid margins, conjunctiva, corneal surface, and tear film. The examination was performed before tear testing to exclude additional ocular pathology.

Keratometry

Corneal curvature was measured using a manual keratometer. Readings were taken for both principal meridians: horizontal (K1) and vertical (K2). Each participant was seated comfortably with proper head positioning (chin on rest and forehead against the support). The instrument was aligned with the patient's visual axis and the mires were focused at the central cornea.

Three consecutive readings were taken for each eye, and the mean value was recorded for analysis. Keratometry values were documented in diopters (D) at baseline and at each follow-up visit.

Schirmer Test

The Schirmer I test was performed to evaluate tear secretion. The test was conducted without topical anesthesia to measure combined basal and reflex tearing. A standardized Schirmer strip was folded and placed at the lateral third of the lower conjunctival fornix.

Participants were instructed to gently close their eyes during the procedure. After five minutes, the strip was removed and the length of wetting was measured in millimeters. The test was performed bilaterally in the same clinical environment to maintain uniformity.

Frontier in Medical & Health Research
ISSN: (e) 3007-1607 (p) 3007-1593

Tear Break-Up Time (TBUT)

TBUT was measured to assess tear film stability. A fluorescein strip was gently applied to the inferior palpebral conjunctiva, and the participant was asked to blink several times to ensure even distribution of dye across the tear film.

Using a cobalt blue filter under slit lamp illumination, the corneal surface was observed. The participant was then instructed to keep the eyes open without blinking. The interval between the last blink and the first appearance of a dark spot on the cornea was measured using a stopwatch.

TBUT was recorded in seconds. The test was repeated three times per eye, and the mean value was used as the final TBUT score.

Data Collection Procedure

After obtaining ethical approval, psoriasis patients fulfilling the eligibility criteria were recruited from Madina Teaching Hospital. At the baseline visit, demographic information such as age, gender, and medical history was recorded. A complete ocular examination was conducted to ensure that participants met the study criteria.

Baseline measurements of keratometry, Schirmer test, and TBUT were obtained before initiating Curcuma longa supplementation. Participants were then provided detailed instructions regarding dosage, administration, and the importance of follow-up visits.

Follow-up visits were scheduled monthly for three months. During each visit, the same tests were repeated using the same procedure and equipment under similar clinical conditions to reduce measurement variability.

All clinical readings were documented immediately in a structured self-designed proforma to ensure accuracy. Data were later entered into SPSS software for analysis while maintaining confidentiality.

Statistical Analysis

Data were analyzed using IBM SPSS version 23. Descriptive statistics were calculated for all parameters, and results were expressed as mean ± standard deviation. Repeated Measures ANOVA was applied to evaluate changes in keratometry, Schirmer test, and TBUT over the follow-up period. A p-value of less than 0.05 was considered statistically significant.

Ethical Considerations

Ethical approval was obtained from the Ethics Committee of Madina Teaching Hospital, Faisalabad, before the initiation of the study. The research was conducted according to institutional guidelines and in accordance with the Declaration of Helsinki.

All participants were informed about the study purpose, procedures, duration, and possible benefits. Written and verbal informed consent was obtained prior to enrollment. Participation was voluntary, and individuals were informed of their right to withdraw at any stage without any penalty. Confidentiality was strictly maintained. Patient identities were not disclosed, and all records were securely stored. Participants were screened for contraindications to Curcuma longa, and safety monitoring was maintained throughout the study period.

RESULTS

4.1 Age Distribution

Sixty eyes of 30 psoriatic patients were analyzed. Participants' ages ranged from 20 to 35 years. The mean age was **27.48 ± 5.02 years**, indicating that most subjects were young adults within the selected inclusion range.

Table 1: Descriptive Statistics of Age

Variable	N	Mean	Std. Deviation
Age (years)	60	27.48	5.024

4.2 Gender Distribution

Among the participants, **32 (53.3%) were male** and **28 (46.7%) were female**, showing a slightly higher proportion of male patients.

Frontier in Medical & Health Research
ISSN: (e) 3007-1607 (p) 3007-1593

Table 2: Frequency Distribution of Gender

Gender	Frequency	Percent (%)
Male	32	53.3
Female	28	46.7
Total	60	100.0

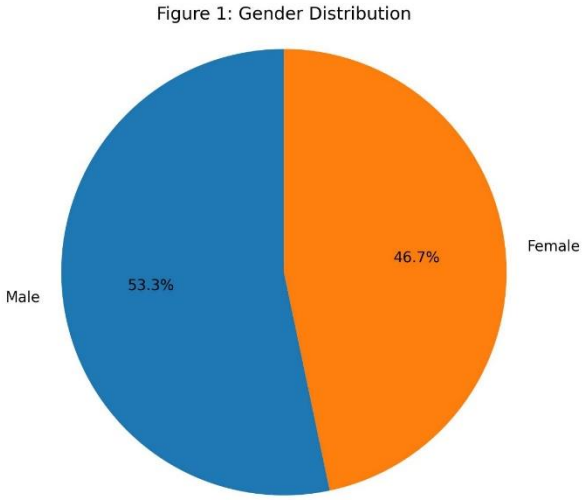

Figure 1: Pie chart shows gender distribution

4.3 Normality of Baseline Data

The Shapiro–Wilk test was used to assess normality of baseline variables. All parameters showed p-values greater than 0.05, indicating normal distribution. Therefore, repeated measures ANOVA was considered appropriate for further analysis.

Table 3: Shapiro–Wilk Test for Normality (Baseline Data)

Variable	Statistic	df	Sig. (p-value)
Keratometry	0.961	60	0.051
TBUT	0.963	60	0.066
Schirmer Test	0.976	60	0.282

Histograms confirmed approximate normal distribution for all three parameters.

Frontier in Medical & Health Research
ISSN: (e) 3007-1607 (p) 3007-1593

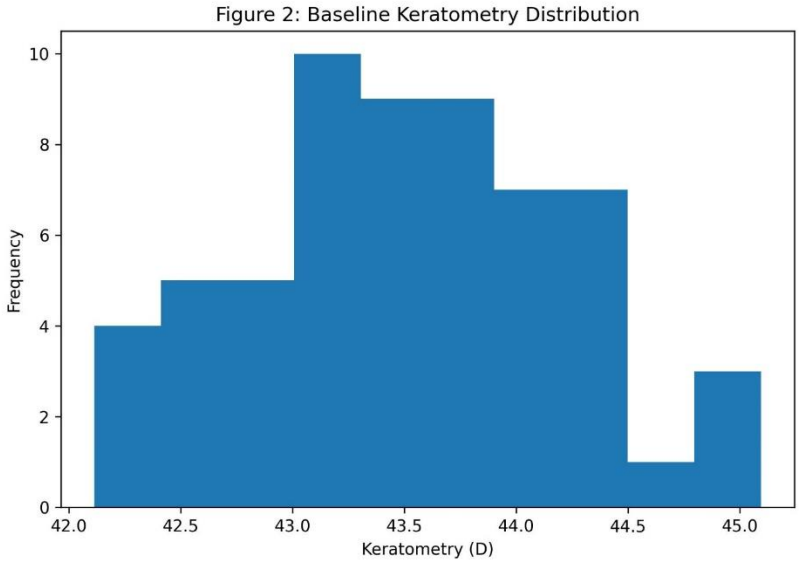

Figure 2: Baseline keratometry distribution

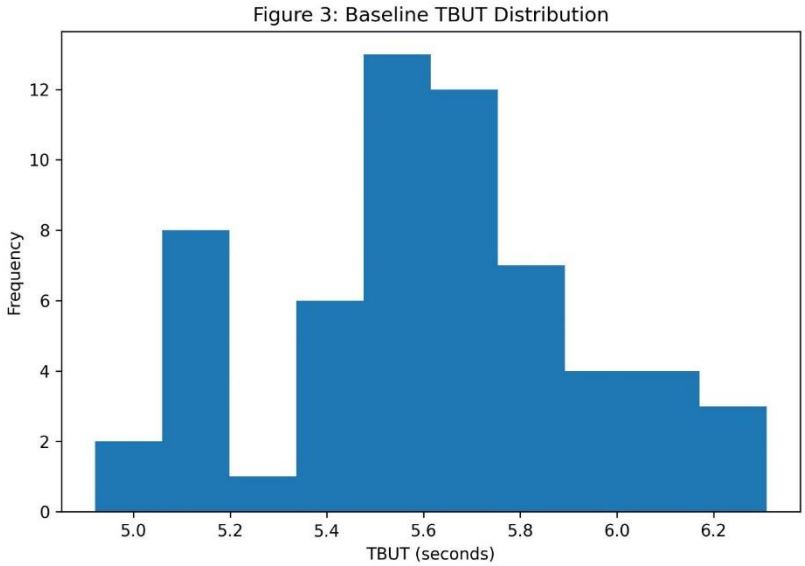

Figure 3: Baseline TBUT distribution

Frontier in Medical & Health Research
ISSN: (e) 3007-1607 (p) 3007-1593

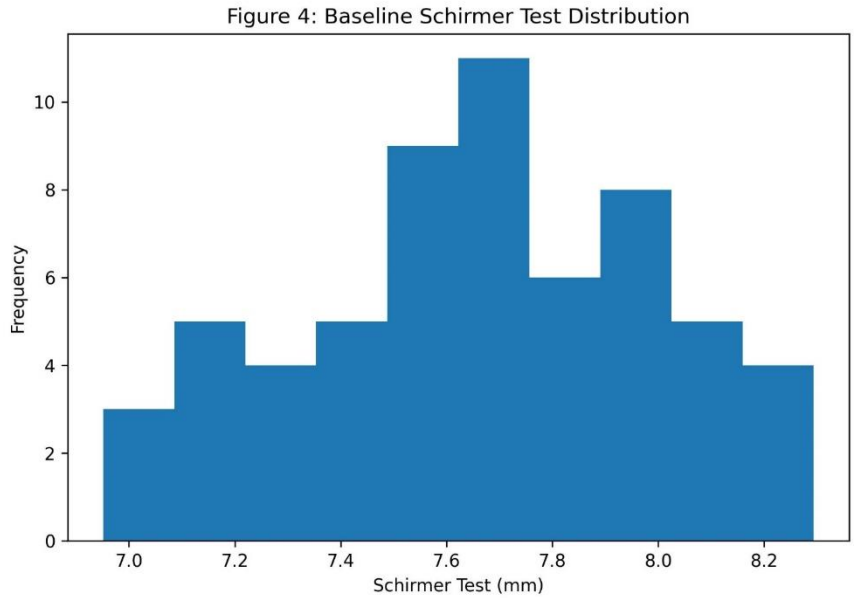

Figure 4: Baseline Schirmer test distribution

4.4 Keratometry Readings

Mean keratometry values showed a gradual reduction over time. Baseline mean was **43.65 ± 0.78 D**, which decreased to **43.45 ± 0.78 D** at the first follow-up, **43.29 ± 0.79 D** at the second follow-up, and **43.11 ± 0.78 D** at the third follow-up.

Repeated measures ANOVA demonstrated a statistically significant change over time (**$p < 0.001$**). The Greenhouse–Geisser correction value was **0.617**, supporting the validity of the analysis.

Table 4: Descriptive Statistics of Keratometry (Diopters)

Time Point	Mean	Std. Deviation	p-value	Greenhouse-Geisser
Baseline	43.6458	0.78182	<0.001	0.617
1st Follow-up	43.4507	0.78100	<0.001	
2nd Follow-up	43.2922	0.78773	<0.001	
3rd Follow-up	43.1107	0.78467	<0.001	

Pairwise Comparison

All time intervals showed significant differences (**$p < 0.001$**), indicating progressive corneal flattening.

Table 5: Pairwise Comparison of Keratometry

Comparison	Mean Difference	Std. Error	Sig.
Baseline vs 1st	0.195	0.009	0.000
Baseline vs 2nd	0.354	0.014	0.000
Baseline vs 3rd	0.535	0.017	0.000

Frontier in Medical & Health Research
ISSN: (e) 3007-1607 (p) 3007-1593

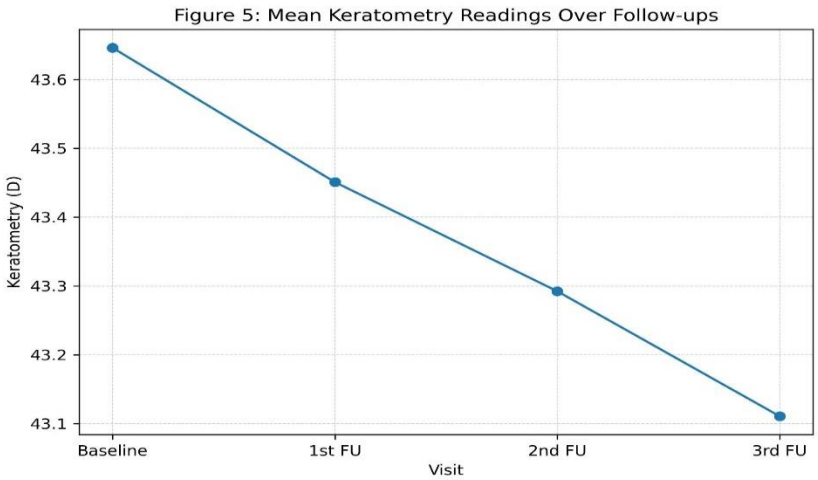

Figure 5: Line graph shows gradual decline in keratometry readings over three months.

4.5 Tear Break-Up Time (TBUT)

Baseline TBUT was **5.62 ± 0.31 seconds**, reflecting tear film instability. A steady increase was observed at each follow-up:

- 1st follow-up: **7.47 ± 0.30 seconds**
- 2nd follow-up: **9.26 ± 0.32 seconds**
- 3rd follow-up: **10.62 ± 0.34 seconds**

Repeated measures ANOVA showed highly significant improvement (**$p < 0.001$**). The Greenhouse–Geisser value was **0.354**.

Table 6: Descriptive Statistics of TBUT (Seconds)

Time Point	Mean	Std. Deviation	p-value	Greenhouse-Geisser
Baseline	5.6213	0.30638	<0.001	0.354
1st Follow-up	7.4717	0.30482	<0.001	
2nd Follow-up	9.2550	0.32124	<0.001	
3rd Follow-up	10.6150	0.34387	<0.001	

Table 7: Pairwise Comparison of TBUT

Comparison	Mean Difference	Std. Error	Sig.
Baseline vs 1st	-1.850	0.058	0.000
Baseline vs 2nd	-3.634	0.060	0.000
Baseline vs 3rd	-4.994	0.062	0.000

Frontier in Medical & Health Research
ISSN: (e) 3007-1607 (p) 3007-1593

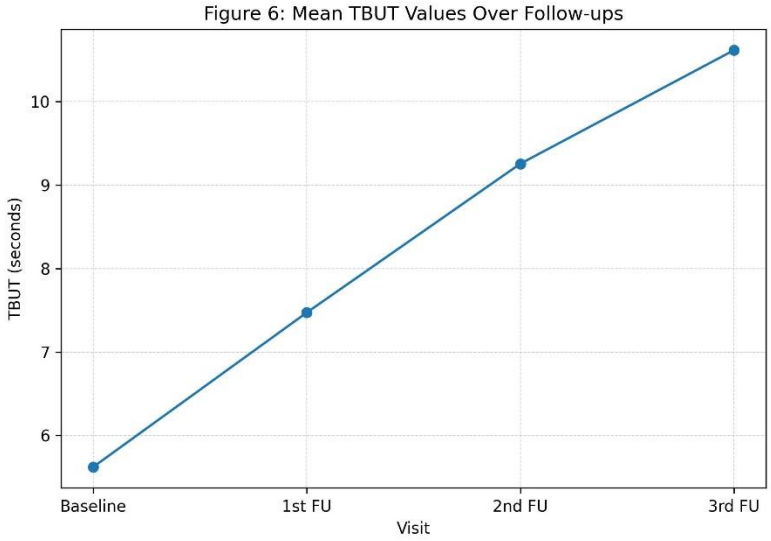

Figure 6: Line graph shows progressive improvement in TBUT across follow-ups

4.6 Schirmer Test

Baseline Schirmer value was **7.65 ± 0.35 mm**. Progressive improvement was observed at each follow-up:

- 1st follow-up: **8.76 ± 0.37 mm**
- 2nd follow-up: **9.55 ± 0.43 mm**
- 3rd follow-up: **10.35 ± 0.43 mm**

Repeated measures ANOVA confirmed statistical significance (**$p < 0.001$**). Greenhouse–Geisser value was **0.786**.

Table 8: Descriptive Statistics of Schirmer Test (mm)

Time Point	Mean	Std. Deviation	p-value	Greenhouse-Geisser
Baseline	7.6467	0.35053	<0.001	0.786
1st Follow-up	8.7642	0.36859	<0.001	
2nd Follow-up	9.5542	0.42579	<0.001	
3rd Follow-up	10.3500	0.42526	<0.001	

Table 9: Pairwise Comparison of Schirmer Test

Comparison	Mean Difference	Std. Error	Sig.
Baseline vs 1st	-1.118	0.052	0.000
Baseline vs 2nd	-1.907	0.059	0.000
Baseline vs 3rd	-2.703	0.059	0.000

Frontier in Medical & Health Research
ISSN: (e) 3007-1607 (p) 3007-1593

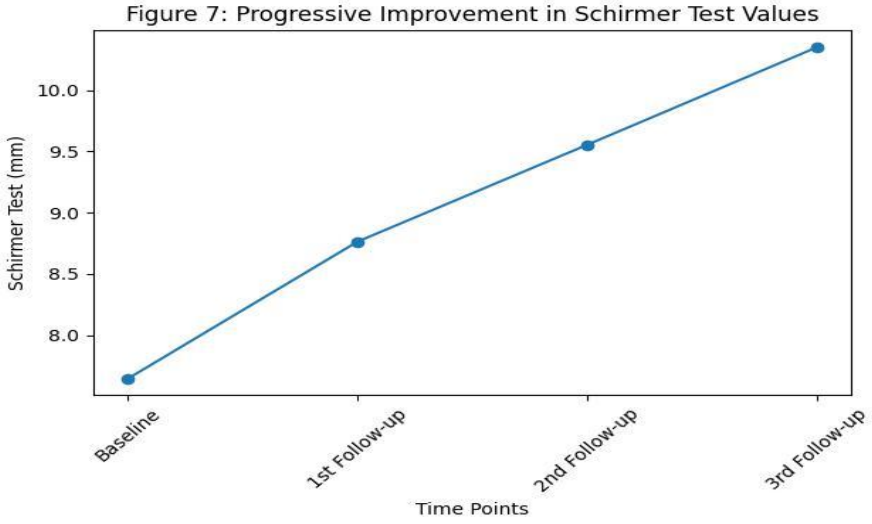

Figure 7: Line graph showing steady increase in tear secretion.

Overall Findings

Across three months of Curcuma longa supplementation:

- Keratometry readings showed gradual flattening.
- TBUT improved significantly, indicating better tear film stability.
- Schirmer values increased steadily, reflecting enhanced tear production.

All changes were statistically significant ($p < 0.001$), demonstrating a consistent therapeutic response.

DISCUSSION

This study investigated the effects of oral *Curcuma longa* tincture supplementation on corneal curvature, tear breakup time (TBUT), and tear secretion in patients with psoriasis. Psoriasis is a chronic immune-mediated inflammatory disorder associated with systemic and ocular manifestations, including dry eye disease (DED), tear film instability, and subtle corneal abnormalities (Boehncke & Schön, 2015; Cruz et al., 2018; Lee et al., 2018). Increasing evidence suggests that inflammatory cytokines such as TNF-α, IL-17, and IL-23 contribute to ocular surface dysfunction in psoriatic patients (Lowes et al., 2007; Di Cesare & Di Meglio, 2016). Given the established anti-inflammatory and antioxidant properties of curcumin, the principal bioactive compound of *Curcuma longa* (Aggarwal & Harikumar, 2009; Hewlings & Kalman, 2017), this study explored its potential therapeutic role in improving ocular surface parameters.

Corneal Curvature (Keratometry)

Keratometric readings demonstrated a statistically significant and progressive reduction over the three-month intervention period ($p < 0.001$). Mean keratometry decreased from 43.64 ± 0.78 D at baseline to 43.11 ± 0.78 D at the third follow-up, indicating mild corneal flattening and stabilization. Although the dioptric changes were subtle, they suggest improvement in corneal surface regularity, potentially reflecting reduced subclinical inflammation.

Normal keratometry values typically range between 42.00 and 44.00 diopters (Akcma et al., 2019). Previous research has reported steeper corneal curvatures in psoriatic patients compared to healthy controls. For example, Akcma et al. (2019) observed mean keratometry values of 44.4 ± 1.5 D in psoriatic patients versus 43 ± 1.6 D in controls. Additionally, corneal biomechanical alterations and keratopathy risk have been documented in psoriasis (Edris et al., 2020; Lee et al., 2018). Chronic inflammation may disrupt corneal epithelial integrity and stromal structure, contributing to these changes.

Frontier in Medical & Health Research
ISSN: (e) 3007-1607 (p) 3007-1593

Curcumin's ability to suppress NF-κB activation and inflammatory mediators (Gupta et al., 2013; Kimura et al., 2008) may explain the observed corneal stabilization. Experimental studies have demonstrated that curcumin preserves corneal epithelial tight junctions and promotes wound healing (Kimura et al., 2008; Wang et al., 2021). Therefore, the improvement in keratometric values observed in this study may be attributed to reduced inflammatory stress on corneal tissue.

Tear Breakup Time (TBUT)

TBUT improved significantly from 5.62 ± 0.31 seconds at baseline to 10.61 ± 0.34 seconds at the final follow-up ($p < 0.001$), indicating marked enhancement in tear film stability. According to TFOS DEWS II criteria, baseline values were consistent with moderate tear film instability. The progressive increase across follow-ups reflects improved lipid layer stability and reduced evaporative tear loss.

Reduced TBUT is well documented in psoriatic patients due to meibomian gland dysfunction and chronic ocular surface inflammation (Her et al., 2013; Taghinezhad, 2018; Shah et al., 2020). Inflammatory cytokines are known to disrupt meibomian gland secretion and tear film homeostasis (Luo et al., 2009). Curcumin exerts immunomodulatory effects by inhibiting pro-inflammatory pathways, including TNF-α, IL-1, and IL-6 (Aggarwal & Harikumar, 2009; Gupta et al., 2013), which may restore glandular function and tear film integrity.

Our findings align with previous clinical research evaluating curcumin in dry eye disease. Mazzolani and Togni (2012) reported approximately a 4-second improvement in TBUT following oral curcumin-phospholipid supplementation over 12 weeks. Similarly, Bianchi (2023) demonstrated significant TBUT enhancement with oral curcumin in patients with DED. Although these studies did not specifically involve psoriatic patients, the comparable magnitude of improvement supports the hypothesis that curcumin improves tear film stability through systemic anti-inflammatory mechanisms.

Tear Secretion (Schirmer Test)

Schirmer test results showed statistically significant improvement, increasing from 7.65 ± 0.35 mm at baseline to 10.35 ± 0.43 mm at the third follow-up ($p < 0.001$). Baseline values indicated mild aqueous tear deficiency, consistent with prior reports describing subnormal Schirmer scores in psoriasis patients even in the absence of overt ocular complaints (Her et al., 2013; Yu et al., 2011).

Systemic inflammation in psoriasis can impair lacrimal gland function, contributing to aqueous deficiency (Lowes et al., 2007). Curcumin's anti-inflammatory and antioxidant actions (Menon & Sudheer, 2007; Hewlings & Kalman, 2017) may protect lacrimal gland tissue and enhance tear production. Experimental studies have also demonstrated curcumin's protective effects on ocular tissues through modulation of oxidative stress and inflammatory cascades (Franzone et al., 2021; Wang et al., 2021).

Comparable improvements in Schirmer scores have been documented in non-psoriatic dry eye populations receiving curcumin supplementation. Bianchi (2023) reported significant tear volume increases with oral curcumin-phospholipid complexes. Gioia et al. (2024) observed Schirmer increases of 2–3 mm following an 8-week multi-ingredient supplement containing curcumin ($p < 0.001$). These parallel findings strengthen the biological plausibility of curcumin's beneficial effect on tear secretion in inflammatory ocular surface disorders.

Clinical Implications

This study is among the first prospective investigations evaluating oral *Curcuma longa* tincture specifically in a psoriatic population with ocular involvement. The use of objective diagnostic tools—TBUT, Schirmer testing, and keratometry—combined with repeated measures ANOVA and Greenhouse-Geisser correction enhances the robustness of findings.

Clinically, the results suggest that *Curcuma longa* may serve as a safe, natural adjunct therapy for managing tear film instability and mild corneal changes in psoriasis. Given its affordability and accessibility, curcumin supplementation may be

Frontier in Medical & Health Research
ISSN: (e) 3007-1607 (p) 3007-1593

particularly valuable in resource-limited settings. Its multi-target anti-inflammatory activity (Aggarwal & Harikumar, 2009; Gupta et al., 2013) supports integration into interdisciplinary dermatologic and ophthalmologic care models.

Limitations and Future Directions

The study was conducted in a single hospital setting with a relatively small sample size (n = 30), limiting generalizability. Absence of a placebo-controlled group also restricts causal inference. Future randomized controlled trials with larger populations and longer follow-up periods are recommended. Investigation of topical curcumin formulations, optimized dosing strategies, and long-term ocular biomechanical outcomes would further clarify its therapeutic potential.

CONCLUSION

The findings of this study demonstrate that oral supplementation with *Curcuma longa* tincture produced meaningful improvements in ocular surface health among patients with psoriasis. Over the three-month follow-up period, participants showed progressive enhancement in tear film stability, tear secretion, and corneal curvature measurements. Tear breakup time increased steadily, indicating improved tear film quality and reduced evaporation. Schirmer test values also rose to near-normal levels, reflecting better aqueous tear production. In addition, keratometric readings showed mild but consistent corneal flattening, suggesting stabilization of subtle inflammatory changes affecting the cornea.

Psoriasis is widely recognized as a systemic inflammatory condition, and its ocular involvement is often underdiagnosed or overlooked. The improvements observed in this study support the concept that controlling systemic inflammation can positively influence ocular surface function. The anti-inflammatory and antioxidant properties of curcumin likely contributed to restoring lacrimal gland activity, improving meibomian gland function, and reducing subclinical corneal inflammation.

Although the degree of change in corneal curvature was modest, the consistent pattern across all follow-up visits strengthens the reliability of the results. More importantly, the marked improvement in tear film parameters highlights the potential of *Curcuma longa* as a supportive therapy for dry eye manifestations associated with psoriasis.

Overall, this research provides encouraging clinical evidence that oral *Curcuma longa* tincture may serve as a safe and accessible adjunct in managing ocular surface alterations in psoriatic patients. Further controlled studies are necessary to confirm these findings and to establish standardized therapeutic guidelines.

RECOMMENDATIONS

Based on the outcomes of this study, several recommendations can be proposed:

1. **Adjunctive Use in Clinical Practice:**
   Curcuma longa tincture may be considered as a complementary therapy for psoriatic patients experiencing symptoms of dry eye or tear film instability, particularly in cases where long-term anti-inflammatory support is required.
2. **Early Ocular Screening in Psoriasis:**
   Dermatologists and ophthalmologists should collaborate to ensure early ocular evaluation of psoriatic patients, even when symptoms are mild or absent, as subclinical tear film abnormalities are common.
3. **Larger Controlled Trials:**
   Future research should involve randomized, placebo-controlled trials with larger sample sizes to confirm therapeutic efficacy and eliminate potential bias.
4. **Long-Term Follow-Up Studies:**
   Extended observation periods are recommended to determine whether the improvements in tear production and corneal stability are sustained over time.
5. **Dose Optimization and Formulation Research:**
   Studies comparing different formulations (e.g., bio-enhanced oral preparations or topical curcumin drops)

Frontier in Medical & Health Research
ISSN: (e) 3007-1607 (p) 3007-1593

and varying dosages would help identify the most effective and safe regimen.

6. **Exploration in Other Inflammatory Ocular Conditions:**
   Since curcumin targets inflammatory pathways, its role should be investigated in other ocular surface disorders such as meibomian gland dysfunction, autoimmune dry eye, and uveitis-associated surface disease.
7. **Patient Education:**
   Psoriatic patients should be informed about potential ocular complications and the availability of supportive natural therapies alongside standard medical care.

In conclusion, while *Curcuma longa* tincture shows promising benefits for ocular health in psoriasis, comprehensive research is essential before it can be incorporated into standardized treatment protocols.

REFERENCES

Aggarwal BB, Harikumar KB. Potential therapeutic effects of curcumin, the anti-inflammatory agent, against cancer, cardiovascular, autoimmune, neurodegenerative, and other diseases. Int J Biochem Cell Biol. 2009;41(1):40-59. doi:10.1016/j.biocel.2008.06.010

Agarwal R, Gupta SK, Srivastava S, et al. Therapeutic potential of Curcuma longa in ophthalmic diseases. Expert Opin Drug Discov. 2009;4(2):147-158. doi:10.1517/17460440802666034

Akram M, Shahab-Uddin, Usmanghani K, et al. Curcuma longa and curcumin: a review article. Rom J Biol Plant Biol. 2010;55(2):65-70.

Allegri P, Mastromarino A, Marina R. Curcumin and eye disease: from the bench to the clinic. Ann Eye Sci. 2019;4(6):1-12. doi:10.21037/aes.2019.06.01

Allegri P, Rosa R, Masala A, et al. Clinical effectiveness of a new oral curcumin formulation in acute non-infectious uveitis macular edema: a 12-month observational study. Eur Rev Med Pharmacol Sci. 2022;26(1):46-53. doi:10.26355/eurrev_202201_27714

Amedi ST, Zangana SN. High sensitivity C-reactive protein in psoriasis: a marker of disease severity and cardiovascular risk. Ann Rom Soc Cell Biol. 2021;28:11820-11827.

Anand P, Kunnumakkara AB, Newman RA, Aggarwal BB. Bioavailability of curcumin: problems and promises. Mol Pharm. 2007;4(6):807-818. doi:10.1021/mp700113r

Antiga E, Bonciolini V, Volpi M. Oral curcumin (Meriva) as adjuvant treatment of psoriasis: a prospective clinical trial. Clin Cosmet Investig Dermatol. 2015;8:463-470. doi:10.2147/CCID.S74003

Bhowmik D, Chiranjib KP, Kumar K, et al. Turmeric: an herbal and traditional medicine. J Pharmacogn Phytochem. 2013;2(5):115-121.

Bianchi F, et al. Oral curcumin-phospholipid complex in dry eye disease. Front Ophthalmol. 2023;3:1181234. doi:10.3389/fopht.2023.1181234

Boehncke WH, Schön MP. Psoriasis. Lancet. 2015;386(9997):983-994. doi:10.1016/S0140-6736(14)61909-7

Borovkova MV, Babenko AN, Kuzina OS. Study of the toxicity of calendula tinctures with different ethanol content. Innovations Life Sci. 2022;7:214-216.

Cruz NFSD, Brandão LS, Cruz SFSD, et al. Ocular manifestations of psoriasis. Arq Bras Oftalmol. 2018;81(3):219-225. doi:10.5935/0004-2749.20180044

Chintada A. Ocular manifestations in moderate-to-severe psoriasis in India: a prospective observational study. Indian J Ophthalmol. 2022;70(9):3328-3332. doi:10.4103/ijo.IJO_311_22

Frontier in Medical & Health Research
ISSN: (e) 3007-1607 (p) 3007-1593

Di Cesare A, Di Meglio P. The IL-23/Th17 axis in the immunopathogenesis of psoriasis. J Invest Dermatol. 2016;136(8):1600-1602. doi:10.1016/j.jid.2016.06.017

Edris NA, Arfeen SA, Mosaad R, et al. Evaluation of corneal biomechanical parameters in psoriasis patients: a controlled study. Clin Ophthalmol. 2020;14:1833-1837. doi:10.2147/OPTH.S251407

El-Saadony MT, Yang T, Korma SA, et al. Impacts of turmeric and curcumin on human health. Front Nutr. 2023;9:1040259. doi:10.3389/fnut.2022.1040259

Ejaz A, Suhail M, Iftikhar A. Psoriasis in Pakistani population: associations, comorbidities, and hematological profile. J Pak Assoc Dermatol. 2016;9(1):90.

Franzone F, Nebbioso M, Pergolizzi T, et al. Anti-inflammatory role of curcumin in retinal disorders. Exp Ther Med. 2021;22(1):790. doi:10.3892/etm.2021.10169

Ghalamkarpour F. Ocular findings in patients with psoriasis: side effects of treatment or disease itself? J Dermatolog Treat. 2020;31:980. doi:10.1080/09546634.2019.1605143

Gioia N, Gerson J, Ryan R, et al. Multi-ingredient supplement improves ocular symptoms and tear production in dry eye disease. Front Ophthalmol. 2024;4:1362113. doi:10.3389/fopht.2024.1362113

Griffiths CEM, Barker JN. Pathogenesis and clinical features of psoriasis. Lancet. 2007;370(9583):263-271. doi:10.1016/S0140-6736(07)61128-3

Ghoushi E, Poudineh M, Parsamanes N, et al. Curcumin as a regulator of Th17 cells: unveiling the mechanisms. Food Chem Mol Sci. 2024;100:198

Guo X, Li C, Shen Y, et al. Intranasal nanomicellar curcumin accelerates corneal epithelial wound healing in diabetic mice. Eur J Pharm Biopharm. 2016;107:858. doi:10.1016/j.ejpb.2016.08.009

Gupta SC, Sung B, Kim JH, et al. Multitargeting by curcumin as revealed by molecular interaction studies. Mol Pharmacol. 2013;81(3):429-441. doi:10.1124/mol.111.075457