Volume 3, Issue 10, 2025

Frontier in Medical & Health Research

ISSN: (e) 3007-1607 (p) 3007-1593

DIAGNOSTIC UTILITY OF LUMBAR SPINE MRI IN THE EVALUATION OF INTERVERTEBRAL DISC BULGE IN ADULTS PRESENTING WITH LOW BACK PAIN

Hafiz Azhan Yaseen[1], Sana Ali[2], Irfan Akram[3], Nimra Shahid[4], Loqman Shah[*5]

*[1, 2, 3, *4]BS-MIT – Department of Radiological Sciences & Medical Imaging Technology (DRS&MIT) - Superior University - Lahore – Punjab – Pakistan*

[5]BSRT (Hons) - MSAHS-MIT- Demonstrator-MIT, Department of Radiological Sciences & Medical Imaging Technology (DRS&MIT) - Superior University - Lahore – Punjab – Pakistan*

[1]hafizazhan276@gmail.com, sana.ali@superior.edu.pk[2], [3]irfanakram0004@gmail.com, [4]nn3653429@gmail.com,[*5]loqmanshah001@gmail.com

DOI: https://doi.org/10.5281/zenodo.17934289

Keywords

Low Back Pain, Disc Desiccation, Disc bulge, Degenerative Changes, MRI

Article History

Received: 15 October 2025

Accepted: 28 November 2025

Published: 15 December 2025

Copyright @Author

Corresponding Author: *

Loqman Shah

Abstract

Background: *Many adults experience pain in the lower back, making it a very common orthopedic disorders and is typically linked with degenerative changes in the lumbar intervertebral discs. Disc bulge signifies an early indicator of disc degeneration that can evolve to herniation or spinal canal stenosis if not diagnosed early. MRI provides high-resolution images of spinal structures and is classified as the reliable standard for assessing intervertebral disc abnormalities due to its enhanced soft-tissue differentiation and non-ionizing nature.*

Objective: *To evaluate the diagnostic utility of lumbar spine MRI in the assessment of intervertebral disc bulge in adults presenting with low back pain.*

Methodology: *This descriptive cross-sectional research was carried out at Shareef Medical City Hospital on 113 adult patients referred for lumbar spine MRI. Demographic and clinical data were recorded. MRI findings were analyzed for the presence of disc bulge, level of involvement, type of bulge, disc desiccation, thecal sac indentation, and nerve root compression. Data analysis was carried out in SPSS version 26 and associations between variables were assessed through the Chi-square test.*

Results: *Among the 113 participants, 89 individuals (78.8%) exhibited disc bulging. The L4–L5 segment was the most commonly affected (45.1%), followed by L5–S1 (11.5%). Most bulges were classified as non-compressive circumferential types (41.6%). Disc dehydration was observed in 93.8% of participants and nerve root impingement occurred in 47.8%. Analysis using the Chi-square test demonstrated a significant association between patient age and disc dehydration ($p = 0.006$) and between bulge morphology and nerve root compression ($p = 0.007$).*

Conclusion: *Magnetic resonance imaging (MRI) is commonly employed to assess intervertebral disc disorders in adults, with the L4–L5 and L5–S1 levels being affected most frequently. The frequent observation of broad-based disc bulge, along with disc desiccation and thecal sac indentation reveals the MRI importance in detecting early degenerative changes. No significant association was found*

Volume 3, Issue 10, 2025

Frontier in Medical & Health Research

ISSN: (e) 3007-1607 (p) 3007-1593

between pain intensity and disc desiccation. Comprehensively, the high soft-tissue resolution of MRI enables accurate assessment of disc bulge.

INTRODUCTION

Pain in lower back (LBP) is a common symptom associated with intervertebral disc bulges and the highly debilitating condition in the lower section extending from ribcage to gluteal region.[1] Clinically, low back pain (LBP) is categorized into two variants, acute and chronic. Acute LBP is the lumbosacral discomfort that lasts for less than six weeks. Chronic LBP is the recurrent pain that extending with a duration of three months.[2] According to the WHO, the young adults with the age category of 18-39 years are suffering. In most cases, acute episodes of low back pain occurring in 80–90% of patients can progress to chronic conditions if not properly managed.[3] The lumbar region bears the mechanical stress and pressure during daily activities. Consequently, any injury to soft tissues may compromise spinal stability and alignment.[4]

Disc bulge, a condition in which the intervertebral disc pushes (the outer fibrous ring-annulus fibrosus) outward from the spinal cord area, involving more than 25% of the disc circumference.[5] Intervertebral discs are flexible structures situated between the vertebrae. They are made up of a soft inner core called the nucleus pulposus, enclosed by a strong outer layer, the annulus fibrosus, and are bordered by cartilaginous endplates.[6] Due to over time, the intervertebral discs undergo wear and tear known as disc degeneration. Disc degeneration involves progressive alterations. The earliest change is the loss of water content and flexibility called disc desiccation. This change results in reduction in disc height, osteophyte formation and facet arthropathy. All these structural changes weaken the discs and trigger the disc bulging.[7]

Several contributing factors consisting of abnormal postures, disc loading, vascular ingrowth and abnormalities in collagen and proteoglycan and loss of collagen and water within the nucleus pulposus of IVD are core biomechanical factors.[8] Disc bulge is mainly associated with radiation of pain to the right lower limb or both limbs. Radiation to the both lower limbs have greater prevalence.[9] Typically, disc bulges are distinguished on the basis of the extent of their circumference. One of the common disc bulge, circumferential bulge in which the disc extends outward from all around the disc that encircles the entire edge of disc. In comparison, the asymmetrical bulge is the non-uniform extension of disc more than one quarter.[10]

Lumber spine MRI research on a specific population shows that disc DDC are the earliest changes in the intervertebral disc degeneration changes (IDDC) that mostly trigger to diffuse disc bulge and asymmetric disc bulge.[11] Lumber disc bulge is also consistently seen on MRI scans among the individuals who do not manifest clinical symptoms. This highlights that disc bulge does not always correlate with the presence or severity of symptoms.[12] If disc bulge is not diagnoses early, then it progresses to disc protrusion, extrusion, spinal canal stenosis, degenerative endplate changes, lumbar degenerative spondylolisthesis, sciatica, lower extremity radicular pain, muscles weakness and in the severe cases paralysis.[13] MRI, being non-invasive and highly safe, is considered the gold standard for assessing the lumbar spine which gives accurate and detailed images of soft tissues and enhance the visibility of soft tissues.[14]

This investigation focused on assessing the diagnostic utility of lumbar spine MRI for the detection of disc bulges. Disc bulge represents an initial sign of disc degeneration, yet existing literature has primarily emphasized advanced degenerative changes, with limited attention given to disc bulge. This limited representation reduces consistency in diagnostic interpretation. Addressing this gap is essential to strengthen MRI-based evaluation of early disc changes and to improve diagnostic precision.

METHODS

A cross-sectional analytical study was performed within 3 months after synopsis approval.

Frontier in Medical & Health Research

ISSN: (e) 3007-1607 (p) 3007-1593

Utilizing consecutive sampling approach, 113 patients clinically recognized with disc bulge were sampled from the Radiology Department of Shareef Medical City Hospital (Jati Umrah Road, Lahore). The sample size was calculated using the formula $n = Z^2P(1-P)/E^2$, with P=0.08, Z=1.96, and E=0.05, yielding 113. Adults aged 18-60 years, presenting with acute or chronic low back pain were referred for lumbar spine MRI by a Radiologist were included in this study. Patients with a history of spinal surgery, sustained traumatic spinal injuries, spinal infections (tuberculosis of spine or discitis), spinal tumors, malignancies and congenital spinal anomalies (scoliosis and spina bifida) were excluded. Data was retrieved after informed written consent by using pre-assessed tools (data sheets and questionnaire) based as per the following variables: Patient ID, Gender, Age, Patients history of LBP severity, LBP duration, disc bulge level, bulge type and neurological symptoms, MRI findings with disc desiccation, thecal sac indentation and nerve root compression. The collected data entered and analyzed using SPSS version 26. Continuous variables were summarized as mean ± standard deviation (SD), while categorical variables were presented as frequencies and percentages. All data was securely stored using Microsoft Office. HITACHI AIRIS 2 1.5 MRI system with a dedicated spinal coil was used. Patients were positioned supine with proper spine alignment. A systematic survey of the lumbar spine was obtained in sagittal and axial planes. Sagittal T1-weighted and T2-weighted images (slice thickness 3–4 mm, gap ≤1 mm) were acquired to assess vertebral alignment, marrow signal and intervertebral disc morphology. Axial T2-weighted images were obtained at each disc level (L1–S1) to evaluate disc bulge, nerve root compression and canal or foraminal narrowing. In selected cases, sagittal STIR sequence included to detect edema or inflammatory changes. Disc bulge was documented according to location (central, paracentral, foraminal, extraforaminal) and degree of neural compromise.

RESULTS

Our study evaluated 113 individuals with ages ranging from 18 to 60 years (mean 39.27 ± 14.16) who presented with low back pain. Most participants were between 18–30 years (37.2%) and males (53.1%) slightly outnumbered females (46.9%). Chronic low back pain was more frequent (73.5%) than acute pain (26.5%) and the majority (73.5%) had symptoms for more than three months. Neurological findings such as numbness (25.7%) and mild sensory loss (17.7%) were relatively common. MRI analysis revealed that the L4–L5 level was the most affected (45.1%), followed by L5–S1 (11.5%) and multilevel involvement (23%). The predominant bulge morphology was non-compressive circumferential (41.6%) and overall, disc bulge was observed in 78.8% of patients. Nerve root compression was noted in 47.8% of cases, while mild to moderate thecal sac indentation was observed in 70.8%. Disc desiccation was highly prevalent (93.8%), mainly at single levels (69.9%). A significant association was observed between age and disc desiccation ($\chi^2 = 12.615$, $p = 0.006$), indicating that disc dehydration increases with advancing age. Similarly, disc level involvement and desiccation were significantly related ($\chi^2 = 15.417$, $p < 0.001$), showing that degeneration worsens as the number of affected levels increases. However, bulge type showed no significant link with desiccation ($\chi^2 = 0.240$, $p = 0.887$), suggesting that disc dehydration is a generalized process not limited to a particular bulge configuration. The relationship between low back pain severity and desiccation was also non-significant ($\chi^2 = 1.018$, $p = 0.313$), indicating that disc dehydration progresses independently of symptom duration. Conversely, nerve root compression varied significantly with bulge type ($\chi^2 = 9.872$, $p = 0.007$) and thecal sac indentation was strongly influenced by bulge morphology ($\chi^2 = 75.793$, $p < 0.001$). Collectively, these results highlight that disc desiccation and degeneration increase with age and level involvement, while certain bulge types are more likely to cause compression effects on neural structures.

Volume 3, Issue 10, 2025

Frontier in Medical & Health Research

ISSN: (e) 3007-1607 (p) 3007-1593

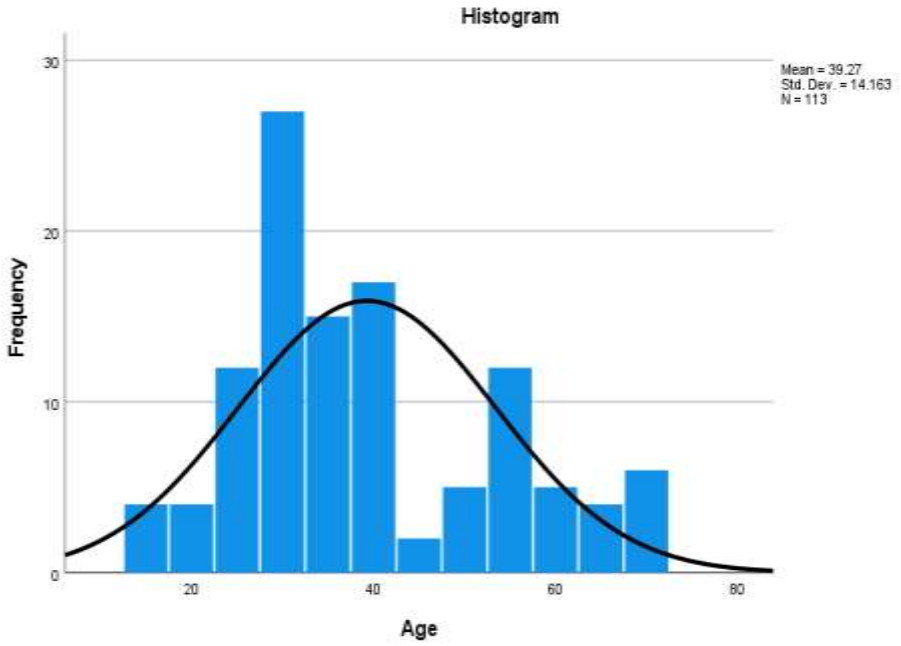

Figure 1: Histogram of Age Statistics

Table 1: Frequency table of Age Distribution

Age Group					
		Frequency	Percent	Valid Percent	Cumulative Percent
Valid	18-30	42	37.2	37.2	37.2
	31-45	39	34.5	34.5	71.7
	46-60	22	19.5	19.5	91.2
	61+	10	8.8	8.8	100.0
	Total	113	100.0	100.0	

Table 2: Frequency table of Gender

Gender					
		Frequency	Percent	Valid Percent	Cumulative Percent
Valid	Female	53	46.9	46.9	46.9
	Male	60	53.1	53.1	100.0
	Total	113	100.0	100.0	

Table 3: Frequency table of LBP Severity

LBP Severity Acute/ Chronic					
		Frequency	Percent	Valid Percent	Cumulative Percent
Valid	Acute	30	26.5	26.5	26.5
	Chronic	83	73.5	73.5	100.0
	Total	113	100.0	100.0	

Frontier in Medical & Health Research

ISSN: (e) 3007-1607 (p) 3007-1593

Table 4: Frequency table of LBP Duration

LBP Duration					
		Frequency	Percent	Valid Percent	Cumulative Percent
Valid	<6 weeks	30	26.5	26.5	26.5
	>3 months	83	73.5	73.5	100.0
	Total	113	100.0	100.0	

Table 10: Frequency table of Disc Desiccation

Disc Desiccation					
		Frequency	Percent	Valid Percent	Cumulative Percent
Valid	Absent	7	6.2	6.2	6.2
	Present	106	93.8	93.8	100.0
	Total	113	100.0	100.0	

Table 11: Frequency table of Disc Levels

Disc Levels Simple					
		Frequency	Percent	Valid Percent	Cumulative Percent
Valid	Multiple levels	26	23.0	23.0	23.0
	None	8	7.1	7.1	30.1
	Single level	79	69.9	69.9	100.0
	Total	113	100.0	100.0	

Table 6: Frequency table of Disc bulge levels

Disc bulge levels					
		Frequency	Percent	Valid Percent	Cumulative Percent
Valid	L2-L3	5	4.4	4.4	4.4
	L2-L3; L3-L4	3	2.7	2.7	7.1
	L3-L4	10	8.8	8.8	15.9
	L3-L4; L4-L5	1	.9	.9	16.8
	L3-L4; L4-L5; L5-S1	3	2.7	2.7	19.5
	L3-L4; L5-S1	5	4.4	4.4	23.9
	L4-L5	51	45.1	45.1	69.0
	L4-L5; L5-S1	14	12.4	12.4	81.4
	L5-S1	13	11.5	11.5	92.9
	None	8	7.1	7.1	100.0
	Total	113	100.0	100.0	

Table 7: Frequency table of Bulge Type

Bulge Type				
	Frequency	Percent	Valid Percent	Cumulative Percent

Frontier in Medical & Health Research

ISSN: (e) 3007-1607 (p) 3007-1593

Valid	Broad-Based Posterior Disc Bulge	18	15.9	15.9	15.9
	Circumferential Disc Bulge	21	18.6	18.6	34.5
	No	24	21.2	21.2	55.8
	Non-Compressive Circumferential Disc Bulge	47	41.6	41.6	97.3
	Para-Central and Circumferential Disc Bulge	3	2.7	2.7	100.0
	Total	113	100.0	100.0	

Table 8: Frequency Table of Bulge Present

Bulge present					
		Frequency	Percent	Valid Percent	Cumulative Percent
Valid	0 (No)	24	21.2	21.2	21.2
	1 (yes)	89	78.8	78.8	100.0
	Total	113	100.0	100.0	

Table 5: Frequency table of Neurological Symptoms

Neurological Symptoms					
		Frequency	Percent	Valid Percent	Cumulative Percent
Valid	Mild sensory loss	20	17.7	17.7	17.7
	No neurological deficit	22	19.5	19.5	37.2
	Normal	26	23.0	23.0	60.2
	Numbness in lower limb	29	25.7	25.7	85.8
	Radiating pain	16	14.2	14.2	100.0
	Total	113	100.0	100.0	

Table 9: Frequency table of Nerve Root Compression

Nerve Root Compression					
		Frequency	Percent	Valid Percent	Cumulative Percent
Valid	No	59	52.2	52.2	52.2
	Yes	54	47.8	47.8	100.0
	Total	113	100.0	100.0	

DISCUSSION

Bhat et al. (2024) conducted a cross-sectional study on 150 adult patients with low back pain using 1.5 Tesla MRI, reporting a high incidence of diffuse disc bulge (87.33%), primarily at lower lumbar levels. Their study emphasized MRI as a reliable tool for detecting degenerative disc changes and correlating findings with patient-reported symptoms. Similarly, our study found a high prevalence of disc bulge (78.8%), particularly at L4–L5 and L5–S1 levels, confirming the common involvement of lower lumbar segments. In addition, our study extended these observations by statistically analyzing associations between disc desiccation, bulge morphology, and neural compression, revealing that while disc desiccation increased with age and level involvement, bulge type significantly affected nerve root compression,

Frontier in Medical & Health Research

ISSN: (e) 3007-1607 (p) 3007-1593

providing more detailed clinical insights than the prevalence data reported by Bhat et al.[15]

Sharma et al. (2022) performed lumbar spine MRI on 98 patients and reported that disc bulge was present in 91% of cases, with disc protrusion in 51% and nerve root compression observed in several participants. They highlighted MRI's ability to differentiate disc bulge types, including symmetrical, asymmetrical, and diffuse, which is important for understanding structural variations in degenerative discs. In our study, non-compressive circumferential bulges were the most common and statistical analysis revealed a strong association between bulge type and neural compression, reinforcing Sharma et al.'s findings regarding the clinical significance of morphology. Additionally, our study evaluated multilevel involvement and disc desiccation, showing that degeneration worsens with increasing affected levels, expanding on their descriptive observations with quantitative correlations.[16]

Saleem et al. (2025) studied 146 young adults using 3T MRI and found disc bulge to be the most common abnormality (26.1%), with multilevel degeneration occurring in about one-third of participants. The most frequently affected levels were L3–L4 and L4–L5, highlighting the predilection of lower lumbar segments for degenerative changes. Similarly, our study identified L4–L5 as the most involved level, followed by L5–S1 and observed significant multilevel disc desiccation in 69.9% of cases. Furthermore, our analysis demonstrated that while disc desiccation increases with age and level involvement, certain bulge morphologies contribute more to nerve root compression and thecal sac indentation.[17]

CONCLUSION

Magnetic Resonance Imaging (MRI) is an important tool for diagnosing intervertebral disc bulges in adults with low back pain. In this study, the L4–L5 and L5–S1 levels were the most commonly involved. The MRI findings seen in a greater proportion of patients such as broad-based disc bulges, with a high prevalence of disc desiccation and mild to moderate thecal sac indentation shows the efficacy of early detection. In statistical analysis, the correlations between age and disc desiccation demonstrated that degenerative changes progress with age. There is no significant correlation between pain severity and disc desiccation. Overall, MRI is highly sensitive for better characterization of disc bulge.

Authors Contribution: All Authors equally contributed to the study and approved the final manuscript.

Conflict of Interest: No conflict of interest.

Funding: No funding received by the authors.

REFREENCES

Shoukat M, Ejaz S, Raza N, Ahmad F, Ghafoor A, Ahmad N. Correlation of low back pain with pathological changes of lumbar spinal segment in young adults: a cross-sectional study. Journal of Islamabad Medical & Dental College. 2024 Jul 17;13(2):271-6.

Yousof M, Din RU, Ahmad M, Khattak S, Ali S. The Prevalence of Pathologies Causing Low Back Pain Using Magnetic Resonance Imaging for Categorization. OMICS J Radiol. 2021;10(4):323.

Rafaqat Z, Aziz R, Naeem AA, Adil HB. Evaluation of Lumbar Spine on MRI in Young Adults with Chronic Backaches. MedERA J CMH LMC. 2024;6(2):106-112.

Beulah A, Sharmila TS, Pramod VK. Disc bulge diagnostic model in axial lumbar MR images using Intervertebral disc Descriptor (IdD). Multimedia Tools and Applications. 2018 Oct;77(20):27215-30.

Hung IY, Shih TT, Chen BB, Guo YL. Prediction of lumbar disc bulging and protrusion by anthropometric factors and disc morphology. International Journal of Environmental Research and Public Health. 2021 Mar 4;18(5):2521.

Raheem HM, Aljanabi M. Studying the bulging of a lumbar intervertebral disc: a finite element analysis. Procedia Structural Integrity. 2020 Jan 1; 28:1727-32.

Frontier in Medical & Health Research

ISSN: (e) 3007-1607 (p) 3007-1593

Devkota S, Rathi H, Lamichhane S. Focal fatty infiltration of the lumbar intervertebral disc: a case report and literature review. Oxford Medical Case Reports. 2025 May; 2025(5):omaf027.

ESWARA S, KALENAHALLI KV, YERRAM S, ITAGI RM, Jose J. Correlation of Magnetic Resonance Imaging findings with Clinical Grading in Lumbar Disc Degeneration: A Cross-sectional Study. JOURNAL OF CLINICAL AND DIAGNOSTIC RESEARCH. 2023 May 1.

Azeem N, Anwar M, Kadri S. Magnetic Resonance Imaging of Lumbar Spine in Lower Backache: A Comparative Study on Gender Basis. Journal of Bahria University Medical and Dental College. 2022 Oct 6;12(04):207-11.

Gaillard F, Yap J, Campos A, et al. Disc bulge. Reference article, Radiopedia.org. 2025 Oct 14.

Khadgi K, Singh TB. Most Common MRI finding in Lumbosacral Degenerative changes in Nepal Police. Nepal Medical Journal. 2021 Nov 4;4(1):7-14.

Varun S, Jishnu J, Sahana S. A Multicenter Hospital Based Study on Prevalence of Lumbar Intervertebral Disc Herniation in Asymptomatic Individuals on MRI. International Journal of Pharmacy Research & Technology (IJPRT). 2025 Mar 6;15(1):66-70.

Tamagawa S, Sakai D, Nojiri H, Sato M, Ishijima M, Watanabe M. Imaging evaluation of intervertebral disc degeneration and painful discs—advances and challenges in quantitative MRI. Diagnostics. 2022 Mar 14;12(3):707.

Mustafa W. Magnetic Resonance Imaging Findings in Lumbosacral Spine among Young Arabic Patients with Back Pain. Khalij-Libya Journal of Dental and Medical Research. 2024 Dec 10:286-91.

Bhat MR, Pratap B, Jha PK, Wani AA, Islam JU. Role of MRI in detection of lumber spine pathologies using 1.5 tesla (MRI). 2024, 21(01), 1157-6.

Sharma BR, Singh S, Timilsina MM. Evaluation of the Diagnostic Utility of Spinal Magnetic Resonance Imaging in Low Back Pain Patients. Nepalese Journal of Radiology. 2022 Jun 30;12(1):30-8.

Saleem R, Khan S, Slehria AU, Aquil H, Halim A. Pattern of lumbar disc degeneration in young adults with low back pain on 3T magnetic resonance imaging machine. JPMA. The Journal of the Pakistan Medical Association. 2025 Apr;75(4):587-91.