Volume 3, Issue 10, 2025

Frontier in Medical & Health Research

ISSN: (e) 3007-1607 (p) 3007-1593

CORRELATION OF MAGNETIC RESONANCE IMAGING FINDINGS IN CERVICAL SPINE DEGENERATION WITH SENSORY AND MOTOR CLINICAL MANIFESTATIONS

Roha Sami[1], Farah Javed[*2], Fahmida Ansari[3], Zaigham Hayat Shah[4], Muhammad Ilyas Ramzan[5]

[1, *2,3,4]*Faculty of Allied Health Sciences, Superior University, Raiwind Road, Lahore 54000, Pakistan*
[5]*King Edward Medical University, Lahore, Pakistan*

[*2]farahjaved@superior.edu.pk

DOI: https://doi.org/10.5281/zenodo.17906616

Keywords
Cervical Spine Degeneration, Cramer's V Nominal Correlation, Disc Buldge, Dessicatory Changes, Radiculopathy

Article History
Received: 12 October 2025
Accepted: 27 November 2025
Published: 12 December 2025

Copyright @Author
Corresponding Author: *
Farah Javed

Abstract

Cervical spine degeneration is a common disorder in ageing populations. Magnetic resonanace imaging has become the best initial modality, while evaluating the cervical spine degeneration. Aim of this study was to correlate the magnetic resonance imaging findings in cervical spine degeneration with sensory and motor clinical manifestations. A total of 219 patients with different sets of motor and sensory deficits were included in this analytical cross-sectional study. Data was collected by using questionnaire/performa. Our patients presented with different sensory and motor clinical manifestations, out of which neck pain was most common and found in 189 (86.3%) patients. Neck pain was followed by muscular spams which were found in 86 (39.33%) patients. In this study, abnormal magnetic resonanace imaging findings like disc buldge (64.4%), dessicatory changes (62.6%), thaecal sac compression (48.9%), loss of signal intensities (37.9%), spinal canal stenosis (34.7%), abnormal disc heights (15.5%), peri-vertebral oedema (5.0%) and kyphosis (0.9%) were observed. Correlation between the clinical manifestations and magnetic resonance imaging findings of cervical spine degeneration was studied. Our study found that neck pain was significantly correlated with disc buldges ($p<0.05$), dessicatory changes ($p<0.01$) and peri-vertebral oedema ($p<0.05$). Radiculopathy was significantly correlated with abnormal disc heights ($p<0.01$), disc buldges ($p<0.05$), spinal canal stenosis ($p<0.01$), loss of signal intensity ($p<0.01$) and dessicatory changes ($p<0.01$). Paraesthesia's were significantly correlated with disc buldges ($p<0.01$), loss of signal intensities ($p<0.05$) and dessicatory changes ($p<0.01$). Magnetic resonance imaging findings in cervical spine degeneration are significantly correlated with sensory and motor clinical manifestations

INTRODUCTION

Degenerative conditions of cervical vertebrae are extremely common neurological complications in aged population, and injuries that include cervical spondylosis or disc herniation may arise when these conditions progress (1). Age-related cervical intervertebral disc degeneration is a degenerative sequlae that almost always affects people beyond the age of 45. Although degenerative alterations, on a radiological scan, are a very common finding in people who are not symptomatic, the existence of degenerative disks in cervical spine is more strongly connected to certain symptoms as compared to the lumbar spine degeneration and also is the main reason behind neck discomfort and other sensory and motor

Frontier in Medical & Health Research

ISSN: (e) 3007-1607 (p) 3007-1593

symptoms(2). According to several epidemiological research, cervical canal stenosis was more common as people aged (3).

According to Grisdela et al., smokers experienced high prevelance of degenerative disks in cervical spine than non-smokers. Therefore, prior to surgery, it is essential to understand the patient's smoking habits if they have cervical disc degeneration. To improve the results of surgery, strategies like nicotine replacement therapy and the use of bone morphogenetic proteins during surgery can be taken into consideration (4). A higher incidence of degenerative cervical disc degeneration and its effects is linked to alcohol usage. Alcohol use can be risky for those with cervical degenerative disc disease and canal stenosis because it can relax muscles, which makes the cervical spine less stable (5). According to studies, the two main symptoms that have improved following surgery are pain and stiffness (6). Patients typically complain of axial neck pain and mobility limitations. Only a tiny percentage of patients may experience hyperreflexia, which is frequently caused by osteophytes and posterolateral disc herniations at the neural foramen. Other signs and symptoms include changes in deep tendon reflexes, muscular atrophy, hypoesthesia, paraesthesia, or weakness expressed by particular nerve root impulses (7).

Radiography is a first-line imaging method that uses X-rays to show the bone structure of the spine, evaluate the health of the spinal canal, and detect conditions like osteoarthritis and PLL ossification. However, because the spinal cord and nerve roots are difficult to see, radiography has not been accepted as the gold standard for spine diagnostic workup. Magnetic resonance imaging and computed tomography are second-line imaging methods that help better understand spine disorders and determine the best course of treatment. Although computed tomography is quick, noninvasive, and very accurate, it has several disadvantages. Small lesions, disc disorders, and certain spinal cord abnormalities cannot be accurately detected by CT. Due to the radiography and CT's previously described drawbacks, Magnetic resonance Imaging has been regarded as the most accurate diagnostic method for spinal disorders (8).

When it comes to assessing the degree of central and foraminal stenosis, facet arthropathy, and degenerative disc degeneration, MRI is a great tool (9). For functional purposes, the dimensions of the cervical canal and spinal cord at various angles are meticulously established, and magnetic resonance imaging (MR) can assess both soft tissue and skeletal structures (10). In patients with cervical spine disc degenerative disease, posterior disc protrusion, disc space constriction and loss of intervertebral disc signal intensity are noted (11).

1. Material and methodology

2.1. Research Design:

This research employed cross-sectional analytical research design to study the correlation between MRI findings of cervical spine degeneration and their sensory and motor clinical manifestations. The study was conducted in radiology department of Sir Ganga Raam Hospital, Lahore and data was collected in form of questionnaire. The sample size was n= 219. Non-Probability Convenient sampling technique was used. This descriptive study lasted for 4 months. This study included patients with neck pain, radiculopathy and patients with sensory and motor clinical manifestations. This study excluded patients with history of trauma/injury. Patients that have previously undergone a spinal surgery were also excluded.

2.2. Ethical Consideration:

The research was conducted in accordance with the guidelines established by Superior University's ethics committee in Lahore, and the participants' rights will be upheld. Every participant provided written informed permission. All data collecting and information will be kept private. All study participants will maintain their anonymity.

2.3. Data Collection Procedure

After preforming the scan, all the required variables like age, gender, clinical findings history and the radiological features of patients' scan were noted in the questionnaire. All the data was recorded after taking consent from the patient.

Frontier in Medical & Health Research

ISSN: (e) 3007-1607 (p) 3007-1593

Scanning Technique: Standard imaging procedures were employed, including T2-weighted fast spin-echo sequences (TR/TE, 3432/160 milliseconds; slice thickness, 3) and sagittal T1-weighted spin-echo sequences (repetition time [TR]/echo time [TE], 671/17 milliseconds; slice thickness, 3.0 mm; field of view, 24 cm; matrix, 256 200; and number of excitations [NEX], 2). To get axial T2-weighted spin-echo sequences, fat suppression was employed. Microsoft Excel and the statistical program for social sciences (SPSS) version 25 were used to assess and analyze the data.

2.4. Data Analysis Procedure:

The data was assessed and analyzed using the Statistical Package for the Social Sciences (SPSS) version 25. All variables were examined, and all continuous variables were reported as mean standard deviations. Descriptive analysis was used to investigate data distribution. Continuous variables were analysed using mean and standard deviation (SD). In addition, categorical variables were analyzed using the chi-square test.

2. Results:

Patients presented with different sensory and motor clinical manifestations, out of which neck pain was most common and found in 189 (86.3%) patients. Neck Pain was followed by muscular spams which were found in 86 (39.33%) patients. 81 (37%) patients had numb hands, 77 (35.2%) patients had radiculopathies while 69(31.5%) patients presented with paraesthesia's. 59 (26%) patients had generalized body weaknesses, while only 12(5.5%) patients, were found to have gait disturbances and hyperreflexias, each. In present study, abnormal magnetic resonanace imaging findings like disc buldge (64.4%), dessicatory changes (62.6%), thaecal sac compression (48.9%), loss of signal intensities(37.9%), spinal canal stenosis (34.7%), abnormal disc heights (15.5%), peri-vertebral oedema (5.0%) and kyphosis(0.9%) were observed,

The selected variables were examined for associations using a Cramer's V nominal correlation. By using the Cramer's V nominal correlation, correlation between the clinical manifestations and Magnetic resonance Imaging findings of cervical spine degeneration was studied. Our study found that neck Pain was significantly correlated with disc buldges ($p<0.05$), dessicatory changes ($p<0.01$) and peri-vertebral oedema ($p<0.05$). Radiculopathy was significantly correlated with abnormal disc heights ($p<0.01$), disc buldges ($p<0.05$), spinal canal stenosis ($p<0.01$), loss of signal intensity ($p<0.01$) and dessicatory changes ($p<0.01$). Paraesthesia's were significantly correlated with disc buldges ($p<0.01$), loss of signal intensities ($p<0.05$) and dessicatory changes ($p<0.01$). Gait disturbance was found to be significantly correlated ($p<0.05$) with loss of signal intensities.

Age

Age is an important factor in this study as cervical spine degeneration is a condition that is related directly related to the patient's age. Hence, it is an important variable to study. This study included 219 patients in total. The minimum age of patient was 3 years, while the maximum age of patients involved was 85. Mean age was calculated to be 43.38, while the standard deviation was found to be 15.69.

Frontier in Medical & Health Research

ISSN: (e) 3007-1607 (p) 3007-1593

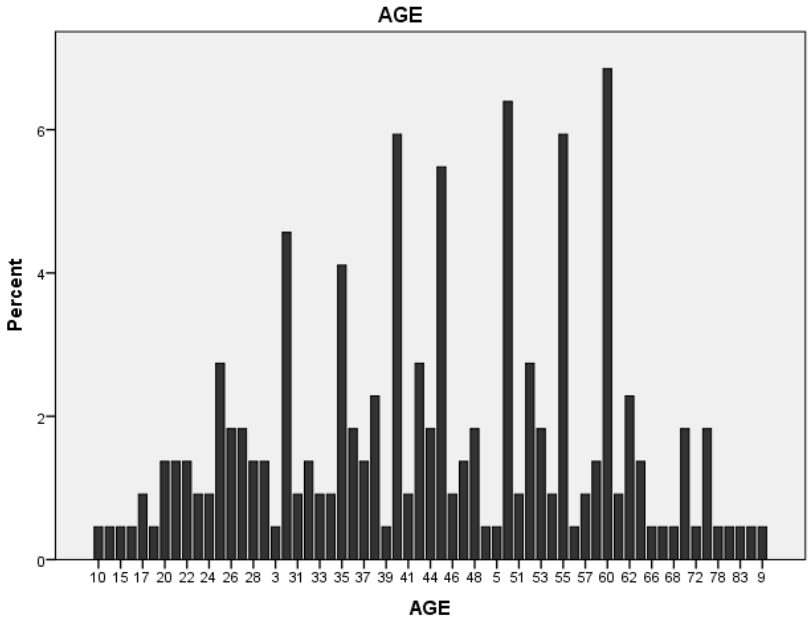

Figure 3.1: The distribution of patients with respect to their ages.

Gender:

Gender is an important variable in this study. Gender can really impact the outcomes of the study as many medical conditions and parameters are dependent on the gender of the patients and vary accordingly. Out of 219 patients included in this study, 101(46.1%) patients were males, while 118(53.9%) patients were females. Gender distribution of this study is given below in the table 3.1.

Table 3.1: The frequency of genders of patients involved in our study

Gender

		Frequency	Percent	Valid Percent	Cumulative Percent
Valid	Female	118	53.9	53.9	53.9
	Male	101	46.1	46.1	100.0
	Total	219	100.0	100.0	

Neck Pain:

Neck pain is one of the most typical signs of cervical spine deterioration. It is a crucial factor in determining the ultimate outcome. Out of the 219 individuals included in this study, 189 (86.3%) reported neck pain. The remaining patients did not have any history of neck pain.

Table 3.2: Frequency of patients with and without Neck Pain

Neck Pain

		Frequency	Percent	Valid Percent	Cumulative Percent
Valid	Absent	30	13.7	13.7	13.7
	Present	189	86.3	86.3	100.0
	Total	219	100.0	100.0	

Frontier in Medical & Health Research

ISSN: (e) 3007-1607 (p) 3007-1593

Radioculopathy

Figure 3.2 explained the frequency distribution of radiculopathuy in patients with the help of a histogram. Out of 219 patients included in this study, 77 patients presented with radiculopathies while 142 patients did not have any radiculopathies.

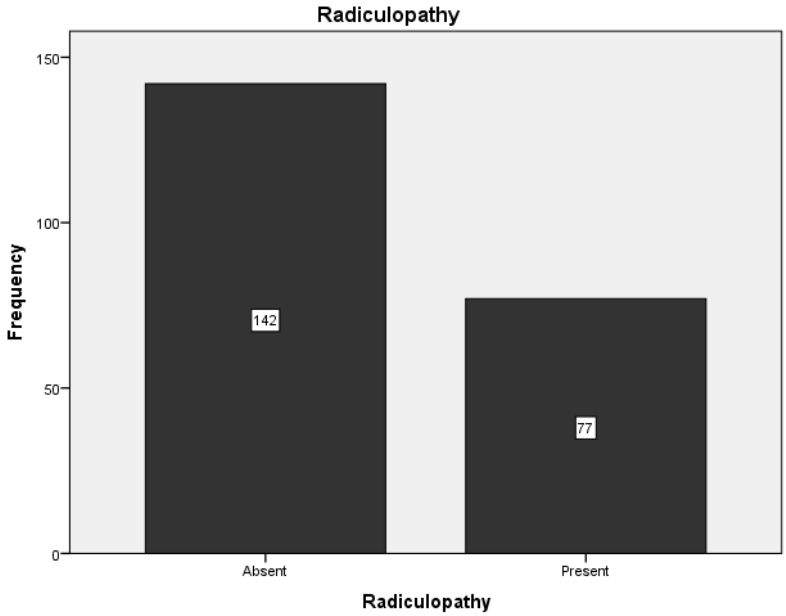

Figure 3.2: Number of patients presented with and without radiculopathy.

Paraesthesis

Paraesthesia refers to the skin sensation like numbness etc. It is an important sensory clinical manifestation of cervical spine degeneration. It is an indicator of CDD. Out of 219 Patients included in this study only 69 people presented with paraesthesia (Figure 3.3).

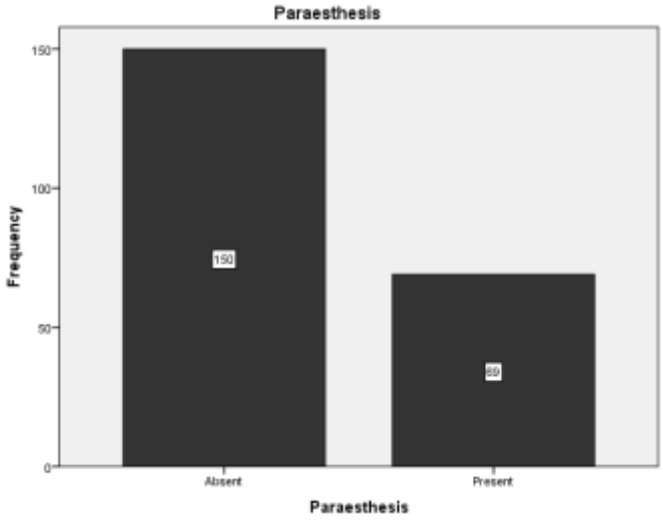

Figure 3.3: The frequency of patients presented with and without Paraesthesis

Weakness:

Weakness is a common sign in patients with cervical spine degeneration. It is important indicator for CDD. Table 3.3 explained the frequency distribution of patients with and without any sort of sensory or motor weakness. In this study, Out of 219 Patients, 59 (26.9%) patients had weakness.

Frontier in Medical & Health Research

ISSN: (e) 3007-1607 (p) 3007-1593

Table 3.3: Frequency distribution of Weakness in patients

GAIT DISTURBANCE:

Weakness

		Frequency	Percent	Valid Percent	Cumulative Percent
Valid	Absent	160	73.1	73.1	73.1
	Present	59	26.9	26.9	100.0
	Total	219	100.0	100.0	

CDD has many motor clinical manifestations that are not quite common yet indicative. Gait Disturbance is also one of them. In our study, it was also found in a scarce number of patients. Out of 219 Patients, only 12(5.5%) patients presented with gait disturbances (Table 3.4).

Table 3.4: Frequency table of Gait Disturbance among patients

Gait Disturbance

		Frequency	Percent	Valid Percent	Cumulative Percent
Valid	Absent	207	94.5	94.5	94.5
	Present	12	5.5	5.5	100.0
	Total	219	100.0	100.0	

Hyperreflexias:

Hyperreflexias is one of the sensory clinical manifestations that are found in patients with cervical spine degeneration. Out of 219 Patients involved in this study, only 12(5.5%) patients presented with hyperreflexias. Figure 3.4 showed the distribution of patients with and without hyperreflexias in a histogra

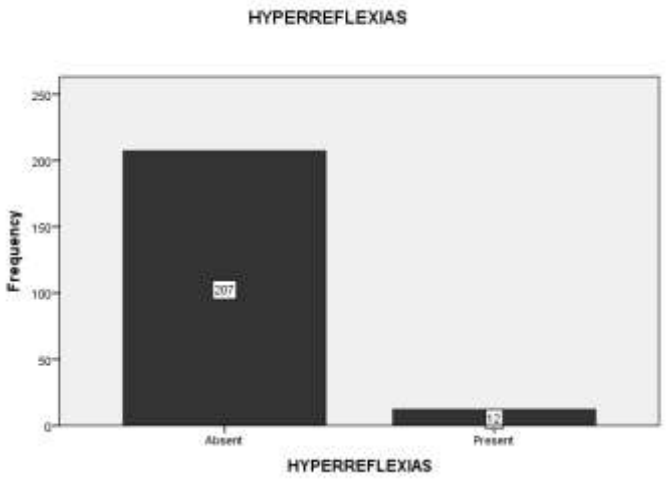

Figure 3.4: Histogram showing frequency of patients with and without hyperreflexias

Muscle spasms:

Muscular spasms could be more common in patients with cervical spine degeneration. It is also a sensory clinical manifestation of CDD. In this study, 86(39.3%) patients had muscular spasms as described in the table 3.5.

Frontier in Medical & Health Research

ISSN: (e) 3007-1607 (p) 3007-1593

Table 3.5: Frequency distribution table of patients with Muscular Spasms

Muscle Spasms

		Frequency	Percent	Valid Percent	Cumulative Percent
Valid	Absent	133	60.7	60.7	60.7
	Present	86	39.3	39.3	100.0
	Total	219	100.0	100.0	

Numb hands

Numbness is an indicator of CDD in patients. It is mostly caused by some nerve compression that causes the numbness in respective hand. Out of 219 patients in this current study, 81(37%) presented with a history of Numb Hands (either one or both).

Table 3.6: Frequency of patients with Numb Hands

Numb Hands

		Frequency	Percent	Valid Percent	Cumulative Percent
Valid	Absent	138	63.0	63.0	63.0
	Present	81	37.0	37.0	100.0
	Total	219	100.0	100.0	

Kyphosis

Kyphoses literally means the curvature of spine, most commonly occurring in thoracic or sacral spine. It is a clinical manifestation of cervical spine degeneration as well. But it is scarcely prevalent in patients with CDD. Out of 219 patients in this study only 2 (0.9%) were presented with Kyphosis (Figure 3.5).

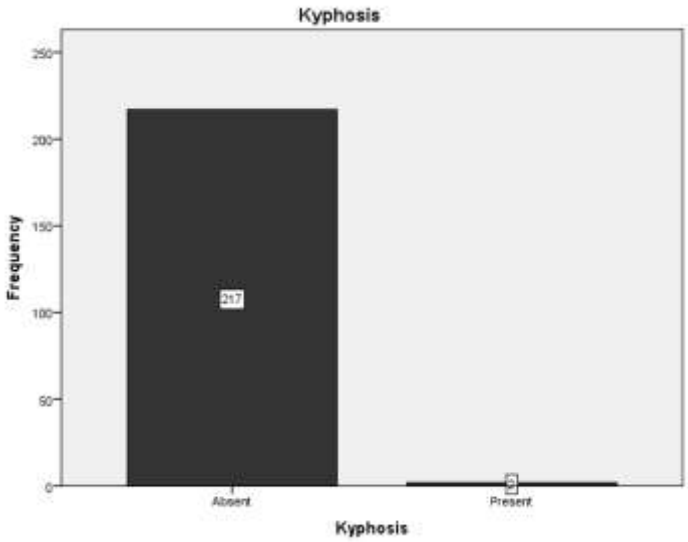

Figure 3.5: Histogramic descriptive representation of patients with Kyphosis

Disc Height

Abnormal disc heights could also lead to diagnosis of cervical spine degeneration. It is a common MRI

Frontier in Medical & Health Research

ISSN: (e) 3007-1607 (p) 3007-1593

finding in CDD. Likewise, in the current study, 34 (15.5%) patients had abnormal disc heights (Table 3.7).

Table 3.7: Descriptive frequencies of patients with normal and abnormal disc heights

Disc Height

		Frequency	Percent	Valid Percent	Cumulative Percent
Valid	Normal	185	84.5	84.5	84.5
	Abnormal	34	15.5	15.5	100.0
	Total	219	100.0	100.0	

Disc buldge

Disc buldging is quite common MRI finding in cervical spine degeneration. It often leads to other complications like nerve compressions etc. Out of 219 patients involved in this study, disk buldges were found in 141(64.4%) patients (Table 3.8).

Table 3.8: Frequency table of patients with disc buldges

Disc Buldge

		Frequency	Percent	Valid Percent	Cumulative Percent
Valid	Absent	78	35.6	35.6	35.6
	Present	141	64.4	64.4	100.0
	Total	219	100.0	100.0	

Spinal canal stenosis

Spinal Canal stenosis could potentially lead to many complications. It is an important MRI finding in Cervical Spine Degeneration as it correlates with other sensory and motor clinical manifestations of CDD. Out of 219 Patients, 76(34.7%) patients had spinal canal stenosis in this study (Table 3.9).

Table 3.9: Spinal Canal Stenosis frequency distribution

Spinal Canal Stenosis

		Frequency	Percent	Valid Percent	Cumulative Percent
Valid	Absent	143	65.3	65.3	65.3
	Present	76	34.7	34.7	100.0
	Total	219	100.0	100.0	

Loss of signal intensity

Loss of signal intensity also suggests the cervical spine degeneration but it needs to be correlated with other factors to determine the reality. In this study, loss of signal intensities on MRI was found in 83 (37.9% patients) while 136 (62.1%) patients had normal signal intensities on MRI (Table 3.10).

Table 3.10: Presence/Absence of Loss of Signal Intensity in Patients' Scans

Loss Of Signal Intensity

Frontier in Medical & Health Research

ISSN: (e) 3007-1607 (p) 3007-1593

		Frequency	Percent	Valid Percent	Cumulative Percent
Valid	Not Seen	136	62.1	62.1	62.1
	Seen	83	37.9	37.9	100.0
	Total	219	100.0	100.0	

Dessicatory changes

Desicatory changes are quite common in CDD and they increase as the patient's age progresses. Likewise, in this study, as average age was above 40, the majority of people had desicatory changes visible on their MRIs. 137(62.6%) patients had dessicatory changes in cervical disks on MRI (Table 3.11).

Table 3.11: Dessicatory Changes Frequency Distribution

Dessicatory Changes

		Frequency	Percent	Valid Percent	Cumulative Percent
Valid	Absent	82	37.4	37.4	37.4
	Present	137	62.6	62.6	100.0
	Total	219	100.0	100.0	

Perivertebral odema

Out of 219 Patients included in our study, only 12(5.0%) patients had peri-vertebral Edema. Peri-vertebral Edema refers to tissue welling that could result from cervical spine injuries. As seen in table 3.12, peri-vertebral edema is not much common MRI finding in CDD.

Table 3.12 : Perivertebral Oedema frequencies are described

Perivertebral Edema

		Frequency	Percent	Valid Percent	Cumulative Percent
Valid	Absent	208	95.0	95.0	95.0
	Present	11	5.0	5.0	100.0
	Total	219	100.0	100.0	

THAECAL SAC COMPRESSION:

Thaecal Sac refers to the sac that encovers the entire spinal cord. It is compression could lead to a lot of complications. It is one of the common indications of cervical spine degeneration. Out of 219 patients in current study, 107(48.9%) patients had a compressed thaecal sac on MRI (Table 3.13).

Table 3.13 : Descriptive frequencies of thaecal sac compression

Thaecal Sac Compression

		Frequency	Percent	Valid Percent	Cumulative Percent
Valid	Absent	112	51.1	51.1	51.1
	Present	107	48.9	48.9	100.0
	Total	219	100.0	100.0	

Frontier in Medical & Health Research

ISSN: (e) 3007-1607 (p) 3007-1593

Correlation matrix of clinical findings of cervical spine degeneration with MRI features

Neck Pain was significantly correlated with Disc buldge ($p<0.05$), Dessicatory Changes ($p<0.01$) and Peri-vertebral edema ($p<0.05$). Radiculopathy was significantly correlated with abnormal disc heights ($p<0.01$), disc buldges ($p<0.05$), spinal canal stenosis ($p<0.01$), loss of signal intensity ($p<0.01$) and dessicaatory changes ($p<0.01$). Paraesthesias were significantly correlated with disc buldges ($p<0.01$), loss of signal intensities ($p<0.05$) and dessicatory changes ($p<0.01$). Gait Disturbance was found to be significantly correlated ($p<0.05$) with loss of signal intensities.

Table 3.14: Correlation matrix of clinical findings of cervical spine degeneration with mri features

	Neck Pain	Radiculopathy	Paraesthesias	Weakness	Gait Disturbance	Hyperreflex	Muscular Spasms		Numb Hand
Kyphosis	0.038								
Disc Height	0.061	.239**							
Disc Buldge	.147*	.448**	.176**						
Spinal Canal Stenosis	0.039	.869**	0.084	0.098					
Loss of Signal Intensity	0.120	.233**	.159*	0.077	.143*				
Dessicatory Changes	.241**	.352**	.179**	0.066	0.020	0.062			
Perivertebral Edema	-.152*	-0.038	-0.021	0.002	0.128	-0.055	-0.099		
Thaecal Sac Compressioon	0.097	0.026	0.006	0.065	0.005	0.086	0.112	0.065	0.098

**Correlation is significant at the 0.01 level (2-tailed).

*Correlation is significant at the 0.05 level (2-tailed).

3. Discussion

Although magnetic resonance imaging is a good tool for assessing cervical degenerative disease, there is no gold standard for its usage. Several categories of disc degeneration have already been documented utilising magnetic resonance imaging to measure signal intensity, bulging, and height of intervertebral discs. Furthermore, the relationships between morphological results and clinical symptoms are still debatable. It is unclear if the approach used to detect disc degeneration using magnetic resonance imaging changes the outcome for relationships with symptoms, or whether there is proof that morphological results are not connected with clinical symptoms.

This study comprised 219 individuals who had clinical signs of cervical disc degeneration. Current research comprised patients ranging in age from 3 to 85 years old. The average age of this research population was 43.28 years old. Li did research in magnetic resonance Imaging on individuals who had modic alterations to examine their parameters, which was similar to current study (12). That study included 266 successive asymptomatic or symptomatic modic alteration individuals with an average age of 50 years. This study included 120 male patients (45.11%) and 146 female patients (54.8%) (12). While in current study, 101 (46.1%) of the 219 patients were male, while 118 (53.9%) were female.

According to Otaki, disc degeneration was seen in 67% of individuals with neck discomfort. In our investigation, patients reported a variety of sensory and motor clinical manifestations, with neck discomfort being the most prevalent (found in 189 (86.3%) individuals) (13). In present study, 37% of patients exhibited numbness in both hands, whereas Coronado did a similar sort of study and found that 35.6% of patients with persistent neck pain exhibited numbness in both or one hand when they correlated Magnetic Resonance Imaging findings with clinical signs (14).

Alghamdi investigated the link between abnormal Magnetic resonance Imaging results and cervical spine deterioration. This study found 52.2% of patients to have spinal canal stenosis, but our study found 34.7% of patients to have spinal canal stenosis (1). Jensen

Frontier in Medical & Health Research

ISSN: (e) 3007-1607 (p) 3007-1593

discovered that 77% of those with neck pain who underwent magnetic resonanace imaging cervical spine had Spinal Canal Stenosis (15,16).

The prevalence of disc bulges was 64.4% in the present study and in Alghamdi's study the frequency was 25.7% (17).In another study conducted by Hashemi, the percentage of disk bulging was found to be 22.1%(18). Dessicatory alterations (62.6%), thaecal sac compression (48.9%), loss of signal intensities (37.9%), aberrant disc heights (15.5%), peri-vertebral oedema (5.0%), and kyphosis (0.9%) were detected in current study. These results was very comparable to the study conducted by the Mustafa where the aberrant disc height was found to be 44.9% and the disc bulging was found to be 42%(19). In another study by Jager HJ, the percentage of subjects with degenerative changes was found to be 88%, comparable to 62.6% in the current study (20). There is a paucity of research to back up the association of Magnetic Resonance Imaging results in cervical spine degeneration. Our research will undoubtedly aid in understanding the relationship between clinical results and Magnetic resonance Imaging data.

This study found that neck Pain was significantly correlated with disc buldges ($p<0.05$), dessicatory changes ($p<0.01$) and peri-vertebral oedema ($p<0.05$). Radiculopathy was significantly correlated with abnormal disc heights ($p<0.01$), disc buldges ($p<0.05$), spinal canal stenosis ($p<0.01$), loss of signal intensity ($p<0.01$) and dessicatory changes($p<0.01$). Paraesthesia's were significantly correlated with disc buldges ($p<0.01$), loss of signal intensities ($p<0.05$) and dessicatory changes ($p<0.01$). Gait disturbance was found to be significantly correlated ($p<0.05$) with loss of signal intensities.

Conclusion:

Neck Pain, Radiculopathies, Paraesthesia and Gait Disturbances are common clinical manifestations in patients with degenerative diseases of cervical spine. These clinical fiindings are significantly correlated the magnetic resonance imaging features like disc buldges, dessicatory changes, abnormal disc heights, loss of signal intensities, spinal cord compression and perivertebral oedema. Hence, it is concluded that specific Sensory and Motor Clinical findings are significantly correlated with specific Magnetic Resonance Imaging findings. These findings highlight the diagnostic value of MRI in identifying patterns of neurological impairment and underscore its role in guiding clinical assessment and targeted treatment strategies. By establishing these correlations, this study contributes to a more precise understanding of the structural-functional relationships in cervical spine pathology, ultimately supporting improved patient management and outcomes.

Acknowledgement: We would like to acknowledge the efforts of all our authors and participants for participating in our study.

Disclaimer: The authors of this study assume no responsibility or liability for any errors or omissions in the content of this article.

Conflict of interest: There was no conflict of interest among authors of this study.

Funding disclosure: There was no funding provided by any external or internal source to this study.

References:

Alghamdi A, Alqahtani A. Magnetic Resonance Imaging of the Cervical Spine: Frequency of Abnormal Findings with Relation to Age. Medicines. 2021 Dec;8(12):77.

Swanson BT, Creighton D. Cervical disc degeneration: important considerations for the manual therapist. J Man Manip Ther. 2022 Jun;30(3):139-153.

Wada K, Tanaka T, Kumagai G, Kudo H, Asari T, Chiba D, Ota S, Kamei K, Takeda O, Nakaji S, Ishibashi Y. A study of the factors associated with cervical spinal disc degeneration, with a focus on bone metabolism and amino acids, in the Japanese population: a cross sectional study. BMC musculoskeletal disorders. 2018 Dec;19:1-1.

Grisdela P, Buser Z, D'Oro A, Paholpak P, Liu JC, Wang JC. Trends analysis of surgical procedures for cervical degenerative disc disease and myelopathy in patients with tobacco use disorder. European Spine Journal. 2017 Sep;26:2386-92.

Frontier in Medical & Health Research

ISSN: (e) 3007-1607 (p) 3007-1593

Arnold PM, Rice LR, Anderson KK, McMahon JK, Connelly LM, Norvell DC. Factors affecting hospital length of stay following anterior cervical discectomy and fusion. Evidence-based spine-care journal. 2011 Aug;2(03):11-8.

Crandall PH, Batzdorf U. Cervical spondylotic myelopathy. J Neurosurg 1966 25(1):57-66.

Peng B, DePalma MJ. Cervical disc degeneration and neck pain. Journal of pain research. 2018;11:2853.

Kim GU, Chang MC, Kim TU, Lee GW. Diagnostic modality in spine disease: a review. Asian Spine Journal. 2020 Dec;14(6):910.

Park HJ, Kim JH, Lee JW, Lee SY, Chung EC, Rho MH, Moon JW. Clinical correlation of a new and practical magnetic resonance grading system for cervical foraminal stenosis assessment. Acta Radiologica. 2015 Jun;56(6):727-32.

Suzuki A, Daubs MD, Hayashi T, Ruangchainikom M, Xiong C, Phan K, Scott TP, Wang JC. Patterns of cervical disc degeneration: analysis of magnetic resonance imaging of over 1000 symptomatic subjects. Global spine journal. 2018 May;8(3):254-9.

Okada E, Matsumoto M, Fujiwara H, Toyama Y. Disc degeneration of cervical spine onMagnetic resonanace Imaging in patients with lumbar disc herniation: comparison study with asymptomatic volunteers. European Spine Journal. 2011 Apr;20(4):585-91.

Li J, Qin S, Li Y, Shen Y. Modic changes of the cervical spine: T1 slope and its impact on axial neck pain. Journal of pain research. 2017 Aug 24:2041-5.

Otaki H, Otani K, Watanabe T, Sekiguchi M, Konno SI. Associations between clinical neck symptoms and various evaluations ofcervical intervertebral disc degeneration by magnetic resonance imaging. Fukushima Journal of Medical Science. 2021;67(3):107-18.

Coronado R, Hudson B, Sheets C, Roman M, Isaacs R, Mathers J, Cook C. Correlation of magnetic resonance imaging findings and reported symptoms in patients with chronic cervical dysfunction. Journal of Manual & Manipulative Therapy. 2009 Jul 1;17(3):148-53.

Harada GK, Alter K, Nguyen AQ, Tao Y, Louie PK, Basques BA, Galbusera F, Niemeyer F, Wilke HJ, An HS, Samartzis D. Cervical spine endplate abnormalities and association with pain, disability, and adjacent segment degeneration after anterior cervical discectomy and fusion. Spine. 2020 Aug 1;45(15):E917-26.

Merali Z, Wang JZ, Badhiwala JH, Witiw CD, Wilson JR, Fehlings MG. A deep learning model for detection of cervical spinal cord compression in MRI scans. Scientific reports. 2021 May 18;11(1):1-1.

Kalichman L, Kim DH, Li L, Guermazi A, Hunter DJ. Computed tomography–evaluated features of spinal degeneration: prevalence, intercorrelation, and association with self-reported low back pain. The spine journal. 2010 Mar 1;10(3):200-8.

Hashemi H, FIROUZNIA K, Soroush H, AMIR OJ, Foghani A, PAKRAVAN M. MRI Findings of Cervical Spine Lesions among Symptomatic Patients and Their Risk Factors.

Mustapha Z, Okedayo M, Ibrahim K, Abba Ali A, Ahmadu MS, Abubakar A, Yusuf M. Cervical spine MRI findings in patients presenting with neck pain and radiculopathy. Int Res J Basic Clin Stud. 2014 Feb 2;2(2):20-6.

Jäger HJ, Gordon-Harris L, Mehring UM, Goetz GF, Mathias KD. Degenerative change in the cervical spine and load-carrying on the head. Skeletal radiology. 1997 Aug;26(8):475-81.