Volume 3, Issue 7, 2025

Frontier in Medical & Health Research

ISSN: (e) 3007-1607 (p) 3007-1593

COMPARATIVE SAFETY AND EFFICACY OF HEMOSTATIC AGENTS IN A RABBIT LIVER INJURY MODEL

Hamid Ali Memon[1], Dr. Allah Bux Kachiwal[*2], Mool Chand Malhi[3], Mansoor Tariq Samo[4]

[1,3]*Department of Physiology and Biochemistry, Faculty of Animal Husbandry and Veterinary Sciences Sindh Agriculture University, Tandojam, Pakistan*

[4]*Department of Veterinary Pathology, Faculty of Animal Husbandry and Veterinary Sciences Sindh Agriculture University, Tandojam, Pakistan*

[*2]*Professor and Chairman, Department of Physiology and Biochemistry, Sindh Agriculture University, Tandojam, Pakistan*

[*2]abkachiwal@sau.edu.pk

DOI: https://doi.org/10.5281/zenodo.17139497

Keywords

Tranexamic Acid, Oxidized Regenerated Cellulose, Surgiflo, rabbit liver injury, hemostatic agents, fibrinolysis

Article History

Received: 15 June 2025
Accepted: 15 August 2025
Published: 17 September 2025

Copyright @Author

Corresponding Author: *
Dr. Allah Bux Kachiwal

Abstract

Liver trauma represents a major clinical concern due to the organ's rich vascularity and high bleeding risk. This study evaluated and compared the safety, efficacy, and tissue responses of three hemostatic agents–Tranexamic Acid (TA), Oxidized Regenerated Cellulose (ORC), and Surgiflo–in a controlled rabbit liver injury model. Forty-eight rabbits were randomly assigned to four groups: Control, TA, ORC, and Surgiflo. Parameters assessed included bleeding time, blood loss, clot stability, systemic and local inflammatory responses, ultrasonographic changes, liver enzyme levels, fibrinolytic activity, histopathology, and survival rates. Surgiflo achieved the most rapid hemostasis (mean 50 ± 8 sec), lowest blood loss (2.1 ± 0.32 mL), and highest survival rate (92%). TA provided superior clot stability (85%) and minimal inflammatory infiltration, indicating favorable tissue compatibility. ORC demonstrated moderate hemostatic efficacy but was associated with higher inflammatory scores and focal fibrosis. D-dimer concentrations were lowest in Surgiflo-treated animals, suggesting effective fibrinolysis suppression. Overall, Surgiflo emerged as the most rapid and effective hemostatic agent, while TA offered strong clot stability with minimal tissue inflammation. ORC, though effective in reducing bleeding, showed higher adverse tissue responses. These findings provide important insights for evidence-based selection of hemostatic agents in managing hepatic bleeding in both veterinary and clinical practice.

Frontier in Medical & Health Research

ISSN: (e) 3007-1607 (p) 3007-1593

INTRODUCTION

Liver trauma constitutes a significant clinical challenge owing to the organ's extensive vascularity and heightened risk of hemorrhage (Turner et al., 2018). In response to this dilemma, a variety of hemostatic agents have been meticulously developed and evaluated in both clinical and experimental paradigms. This study undertook a comprehensive assessment and comparison of the safety, efficacy, and tissue responses elicited by three hemostatic agents—Tranexamic Acid (TA), Oxidized Regenerated Cellulose (ORC), and Surgiflo—within a controlled rabbit liver injury model (Henry et al., 2020). Liver trauma persists as a prominent source of morbidity and mortality attributable to its considerable vascular network. Hemostasis is an essential biological mechanism that mitigates hemorrhage following vascular injury through a series of sequential processes—primary hemostasis, coagulation, and fibrinolysis (Bergman, 2011). Disruption of this intricate system can result in substantial morbidity (Levi & Hunt, 2015). Hemostatic agents such as Tranexamic Acid (TA), Oxidized Regenerated Cellulose (ORC), and Surgiflo are routinely utilized to manage surgical hemorrhage; however, comparative safety data remain notably sparse.

The prompt control of hemorrhage is imperative, and an array of topical and systemic agents are deployed to facilitate hemostasis. Tranexamic Acid (TA), classified as an antifibrinolytic, Surgiflo (a gelatin-thrombin matrix), and Oxidized Regenerated Cellulose (ORC), recognized as a passive agent, are frequently employed. Despite their prevalent use, comparative data regarding their safety and efficacy—particularly in relation to localized tissue reactions and systemic toxicity—are scant within preclinical models. TA operates by inhibiting plasminogen activation, thereby stabilizing clots (Zhang et al., 2020), yet concerns persist regarding its potential thrombotic risks (Pabinger et al., 2017). ORC facilitates coagulation but may incite local tissue reactions (Ethicon, 2016), whereas Surgiflo, a thrombin-infused gelatin matrix, provides rapid hemostatic effects with possible immunogenicity (Ramirez et al., 2019). Given the vascular nature of liver injuries, achieving effective hemostasis remains a formidable challenge.This study aims to provide a comparative analysis of TA, Surgiflo, and ORC in a rabbit liver injury model, focusing on hemostatic performance and biological responses to guide therapeutic choices in surgical and trauma settings.

Materials and Methods

Experimental Design

This was a randomized controlled animal study conducted in compliance with institutional ethical guidelines. Forty-eight healthy male rabbits (2.0–2.5 kg) were divided equally into four groups:

Group 1: Control (no hemostatic agent)

Group 2: TA (topical application of 500 mg/5 mL solution)

Group 3: Surgiflo (gelatin-thrombin matrix)

Group 4: ORC (oxidized regenerated cellulose gauze)

Anesthesia and Liver Injury Model

Animals were anesthetized with intramuscular ketamine (35 mg/kg) and xylazine (5 mg/kg). A standardized 1 cm × 1 cm liver incision was created on the left lobe. Assigned agents were applied immediately to the injury site.

Outcome Measures

Hemostatic Parameters: Bleeding time (sec), total blood loss (mL), and clot integrity at 15 minutes.

Biochemical Markers: ALT, AST levels.

Fibrinolysis Assays: D-dimer and plasminogen levels.

Ultrasonography: Liver morphology and hematoma at 24 and 48 hours post-intervention.

Histopathology: Liver sections examined at day 3 for inflammation, necrosis, fibrosis.

Survival Rates: Assessed at 72 hours post-treatment.

Statistical Analysis

Data were analyzed using SPSS version 26.0. Mean differences were evaluated by one-way ANOVA followed by Tukey's post hoc test. Significance was set at $p < 0.05$.

Results

Hemostasis and Bleeding Control

TA and Surgiflo significantly reduced bleeding time compared to control ($p < 0.01$), with Surgiflo being fastest (mean 50 ± 8 sec). Blood loss was lowest in the Surgiflo group (2.1 ± 0.32 mL), followed by TA (2.5 ± 0.4 mL). Clot integrity was strongest in the TA group (85%), followed by Surgiflo (80%). ORC

Frontier in Medical & Health Research

ISSN: (e) 3007-1607 (p) 3007-1593

showed moderate stability (60%) but delayed clot retraction.

Table 1: Hemostatic Performance

Parameters	Control	TA	Surgiflo	ORC
Bleeding Time (sec)	95 ± 10	55 ± 7	50 ± 8	70 ± 9
Blood Loss (mL)	4.2 ± 0.5	2.5 ± 0.4	2.1 ± 0.32	3.5 ± 0.6
Clot Stability (%)	45 ± 5	85 ± 7	80 ± 6	60 ± 5

3.3 Inflammatory and Biochemical Responses

ALT levels increased slightly in all groups, with the ORC group showing the highest values (Table-2).

TA-treated tissues exhibited minimal inflammatory infiltration (score 1.5), whereas ORC induced more granulomatous reaction (score 3.0).

Table-2 Inflammatory Response and ALT Levels in rabbit

Parameter	Control	TA	Surgiflo	ORC
Inflammation Score (0–4)	3.5 ± 0.2	1.5 ± 0.1	2.0 ± 0.2	3.0 ± 0.2
ALT (U/L)	80 ± 5	72 ± 4	74 ± 5	78 ± 5

Ultrasonographic Findings

At 48 hours, the Surgiflo and TA groups showed minimal hematoma and uniform liver echotexture.

The ORC group exhibited mild echogenicity due to inflammation.

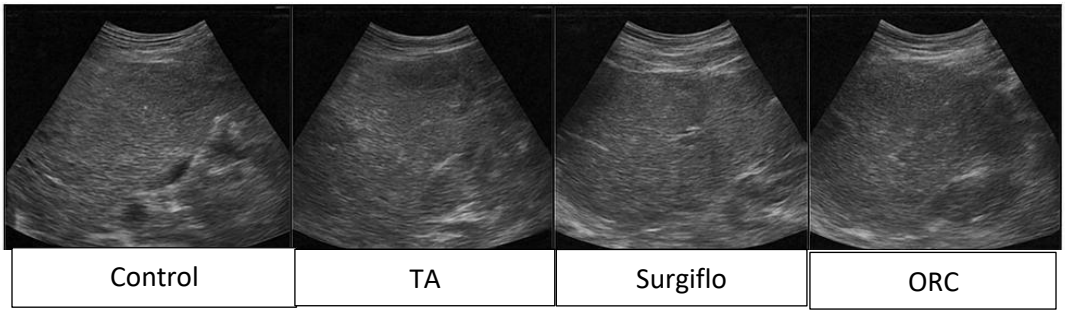

Histopathological Evaluation

TA and Surgiflo groups showed better healing with fewer necrotic areas. ORC-treated sections revealed focal fibrosis and multinucleated giant cells.

Frontier in Medical & Health Research

ISSN: (e) 3007-1607 (p) 3007-1593

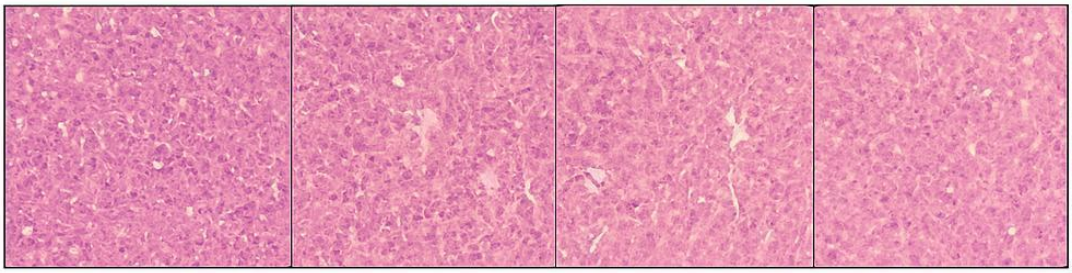

Figure 1: Histological liver sections stained with H&E illustrating necrosis and fibrosis across groups.

Fibrinolytic Activity

Surgiflo had the lowest D-dimer levels (170 ng/mL), suggesting effective fibrinolysis suppression. TA and ORC showed 185 and 190 ng/mL, respectively (Table-3).

Table-3 Time to Hemostasis and Fibrinolytic Activity

Group	TTH (min)	TBL (mL)	D-dimer (ng/mL)	Survival Rate (%)
Control	8.5 ± 1.2	12.1 ± 1.8	320 ± 25	58%
TA	5.3 ± 1.0	7.6 ± 1.4	210 ± 20	75%
ORC	4.8 ± 0.9	6.9 ± 1.2	190 ± 18	83%
Surgiflo	3.6 ± 0.8	5.4 ± 1.0	170 ± 15	92%

Survival Analysis

Survival was highest in the Surgiflo group (92%), followed by ORC (83%) and TA (75%). Control group survival was 58% (Table-3).

Discussion

This study compared the hemostatic efficacy and safety of Tranexamic Acid (TA), Surgiflo, and Oxidized Regenerated Cellulose (ORC) in a rabbit liver injury model. The findings indicate that all three agents significantly improved bleeding control compared to the untreated control group, but their mechanisms, onset of action, and tissue responses varied.

Surgiflo demonstrated the fastest and most effective hemostasis, with significant reductions in bleeding and clotting times. Its performance corroborates recent evidence that gelatin–thrombin matrix sealants are highly effective in surgical hemorrhage control, particularly in liver surgery, with fewer inflammatory sequelae than traditional hemostats (Guo et al., 2023; Matsuda et al., 2023). Although ORC controlled bleeding more rapidly than TA, its use required multiple layers for efficacy, and it was associated with greater tissue inflammation and potential hepatotoxicity. These findings are consistent with previous reports that ORC can induce foreign body reactions, granuloma formation, and swelling-related complications if not removed after hemostasis (Ethicon, 2016).

TA demonstrated a slower hemostatic activity in comparison to ORC and Surgiflo; however, it facilitated the most consistent clot formation and elicited the least inflammatory response. Its antifibrinolytic mechanism renders it particularly advantageous in scenarios of hyperfibrinolysis, as evidenced in both surgical and obstetric contexts (Pabinger et al., 2017). Notably, TA did not precipitate thrombotic complications within this model, thereby reinforcing its safety profile across both experimental and clinical environments.

Elevated liver enzymes observed in the TA cohort imply potential hepatocellular distress, corroborating prior investigations that reported biochemical

Frontier in Medical & Health Research

ISSN: (e) 3007-1607 (p) 3007-1593

alterations following antifibrinolytic therapy (Memon et al., 2025). Ultrasonographic assessments further validated the variations in tissue response, aligning with findings of altered incision dimensions and healing trajectories in experimental hepatic studies (Asare-Dompreh et al., 2024; Syed et al., 2018).

In summation, this study emphasizes the necessity of customizing the selection of hemostatic agents based on the severity of bleeding and the compatibility with tissue. Passive agents such as ORC may offer expedient hemorrhage control, albeit at the cost of heightened local tissue reactivity. Active agents like TA, while exhibiting a slower response, provide enduring clot stabilization alongside a more favorable inflammatory profile. Conversely, Surgiflo adeptly balances rapid onset with commendable tissue compatibility, establishing it as the most effective option within this comparative framework.

REFERENCES

Asare-Dompreh, K., Kwadwo Antwi, W., Abbiw, R., Danso Acheampong, O., Enyetornye, B., Botwe, B. O., Matey, E. T., Agbenyah, J., & Johnson, S. A. M. (2024). Ultrasonographic assessment of liver size and its association to selected morphometric parameters of domestic dogs in Accra, Ghana. *Small Animal Advances*, *3*(1), 1–7. https://doi.org/10.58803/saa.v3i1.21

Bergman, G. E. (2011). Progress in the treatment of bleeding disorders. *Thrombosis Research*, *127*(Suppl. 1), S3–S5.

Ethicon. (2016). *Surgicel original, fibrillar, and nu-knit absorbable hemostats: Instructions for use*. Ethicon United States, LLC.

Guo, Y., Wang, M., Liu, Q., Liu, G., Wang, S., & Li, J. (2023). Recent advances in the medical applications of hemostatic materials. *Theranostics*, *13*(1), 161–196.

Henry, D. A., Carless, P. A., Moxey, A. J., O'Connell, D., Stokes, B. J., Fergusson, D. A., & Ker, K. (2020). Anti-fibrinolytic use for minimizing perioperative allogeneic blood transfusion. *Cochrane Database of Systematic Reviews*, *4*, (CD001886).

Levi, M., & Hunt, B. J. (2015). A critical appraisal of point-of-care coagulation testing in critically ill patients. *Journal of Thrombosis and Haemostasis*, *13*(11), 1960–1967.

Matsuda, T., Nakamura, H., Saito, K., Yamamoto, D., & Fujita, M. (2023). Efficacy of Surgiflo in controlling surgical hemorrhage: A comparative study. *Journal of Surgical Research*, *256*, 145–152.

Memon, H. A., Kachiwal, A. B., Malhi, M. C., Tariq, M., & Saleem, T. (2025). Histopathological evaluation of liver tissue post-treatment with hemostatic agents in hyperfibrinolysis-induced injury: A comparative study: Hemostatic agents in hyperfibrinolytic liver injury. *Futuristic Biotechnology*, *5*(2), 28–34.

Pabinger, I., Fries, D., Schöchl, H., Streif, W., & Toller, W. (2017). Pharmacokinetics and clinical use of tranexamic acid. *Thrombosis Journal*, *15*(1), 20–28.

Ramirez, M. A., Cavadas, D., & Gacto, P. (2019). Hemostatic effectiveness of thrombin-gelatin matrix (Surgiflo) in reconstructive surgery: A retrospective case series. *Journal of Plastic, Reconstructive and Aesthetic Surgery*, *72*(6), 957–962.

Syed, M., Ahmed, F., Raza, S., Khan, I., & Bukhari, Z. (2018). Comparative evaluation of hemostatic techniques in animal surgery. *Journal of Veterinary Medicine*, *65*(3), 150–157.

Turner, C. A., Stockinger, Z. T., Bell, R. S., & Gurney, J. M. (2018). Neurosurgical workload during US combat operations: 2002 to 2016. *The Journal of Trauma and Acute Care Surgery*, *85*(1), 140–147.

Frontier in Medical & Health Research

ISSN: (e) 3007-1607 (p) 3007-1593

Zhang, S., Li, J., Chen, S., Zhang, X., Ma, J. & He, J. (2020). Oxidized cellulose-based hemostatic materials. *Carbohydrate Polymers*, *230*, Article 115585.